

FOGSI-ICOG Good Clinical Practice Recommendations (GCPR)

Updates in Endometriosis Management

Convenor—Asha R Rao

Mentors—Hrishikesh D Pai, Madhuri Patel, Laxmi Shrikhande

Advisors—Sanjay Gupte, Hema Divakar

National Coordinators—CN Purandare, Rishma Dhillon Pai,
Nandita Palshetkar, Jaydeep Tank

Coordinator—Surekha Tayade

Endometriosis Committee

Fogsi Good Clinical Practice Recommendations

Committee Chair-Convenor	: Asha R Rao
Mentors	: Hrishikesh D Pai, Madhuri Patel, Laxmi Shrikhande
Advisors	: Sanjay Gupte, Hema Divakar
National Coordinators	: CN Purandare, Rishma Dhillon Pai, Nandita Palshetkar, Jaydeep Tank
Coordinator	: Surekha Tayade
Contributors	: Pratap Kumar, Padmaja Veeramachaneni, Madhu Goel, Anu Chawla, Riddhi Desai, Damodar R Rao, Suganya Kathir, Rajeswari

Experts

Sanjay Gupte	Mukta Agarwal
Nandita Palshetkar	N Sanjeeva Reddy
Ramani Devi T	Vidya Bhat
Ashwini Bhalerao Gandhi	Manju Khemani
Suvarna Khadilkar	Surekha Tayade
Shobana Mohandas	

Disclaimer: These recommendations for “Endometriosis” have been developed, to be of assistance to obstetricians, gynecologists, consulting physicians, and general practitioners by providing guidance and recommendations for managing women suffering with endometriosis. The recommendations included here should not be viewed as being exclusive of other concepts or as covering all legitimate strategies. The suggestions made here are not meant to dictate how a particular patient should be treated because they neither set a standard of care nor do they guarantee a particular result. To diagnose patients, choose dosages, and provide the best care possible while also taking the necessary safety precautions, clinicians must rely on their own experience and knowledge. The writers or contributors disclaim all responsibilities for any harm and/or damage to people or property resulting from the use or operation of any techniques, goods, guidelines, or ideas presented in this content.

BACKGROUND AND EPIDEMIOLOGY

Endometriosis is a chronic inflammatory progressive gynecological condition characterized by the presence of endometrial glands and stroma outside of the uterine cavity. The main clinical manifestations of the disease are chronic pelvic pain and impaired fertility. The three major forms of endometriosis being the superficial peritoneal endometriosis, ovarian endometrioma, and deep infiltrating endometriosis¹ sometimes extrapelvic involvement seen.

It is estimated that endometriosis affects approximately 10–15% of women of reproductive age, with a prevalence up to 70% in women with chronic pelvic pain.²

The diagnosis of endometriosis in majority of women is often delayed by 4–11 years, causing women to suffer from pain and the long-term effects of this debilitating disease, including infertility.³

The recommended trend today is to give empirical medical treatment and to avoid diagnostic laparoscopy, even though it is considered gold standard for diagnosis.

Being a chronic, progressive, recurrent, debilitating immune-mediated disease, the treatment should be individualized for the short- and long-term benefit of the patient. Medical management should aim at alleviating the symptoms, reducing the size of the lesion, and preventing recurrence. Surgical management should be selective, preferably done only once, at the right time at appropriately equipped center, by experts in the field. Recurrent surgeries should be discouraged as they are counterproductive and lead to more morbidity.

PURPOSE AND SCOPE

This GCPR guideline on endometriosis aims to provide clinical recommendations to improve the quality of healthcare delivery within Indian population. These guidelines were achieved after careful consideration of the scientific evidence available at the time of presentation. In the absence of scientific evidence on certain aspects, a consensus between the developers of the guideline has been obtained. It is an update of the FOGSI-GCPR developed in 2016.

TARGETED AUDIENCE

Obstetricians, gynecologists, midwives, nurses, general practitioners, and other health personnel in charge of the care of women, especially suffering from pain, fertility problem, and other problems due to endometriosis.

METHODOLOGY AND INTERPRETATION OF GRADING SYSTEM OF CURRENT GCPR

The guidelines development group (GDG) followed the grading system in accordance to the American Association of Clinical Endocrinologists (AACE) protocol for the standardized production of clinical practice guidelines. After going through the literature, available evidences, and opinions internationally as well as from the Indian perspective, the GDG formulated the recommendations. Recommendations were organized topic-wise and assigned evidence levels for grades based on the clinical importance and strength of the evidence as mentioned in the following Table:

GRADE	
A	Strongly recommended
B	Intermediate
C	Weak
D	Not evidence based
GPP	Expert/GDG consensus based

The evidence was further classified into four levels as mentioned in the Table below to facilitate the finding to be placed in the grades as mentioned above;

Evidence Level	
1	Meta-analysis of randomized controlled trials (RCTs): High
2	Meta-analysis of nonrandomized prospective or case-controlled trials, nonrandomised controlled trial, prospective cohort study, retrospective case-control study: Moderate
3	Cross-sectional study, surveillance study (registries, surveys, epidemiologic study, retrospective chart review, mathematical modelling of database), consecutive case series, single case reports: Low
4	No evidence (theory, opinion, consensus, review, or preclinical study): Very Low

DIAGNOSIS OF ENDOMETRIOSIS

The diagnosis of endometriosis is often delayed due to the nonexistence of a pathognomonic test or biomarker to detect the disease. The diversity of symptoms that could be considered physiologic responses during menstruation (like pain and discomfort) and also the wide range of reported symptoms that overlap with other gastrointestinal or gynecological causes lead to dilemmas in diagnosis. Early diagnosis needs a high level of awareness of the disease, careful history taking, examination, appropriate use of high-resolution targeted imaging technologies. Diagnostic laparoscopy should be reserved for special cases.

History

- a. Guidelines development group (GDG) recommends that clinician should consider the diagnosis of endometriosis in the presence of [Recommendation GPP].
 - Cyclical and noncyclical signs and symptoms such as dysmenorrhea, deep dyspareunia, dysuria, dyschezia, and pelvic pain.
 - Difficulty in conception
 - Abnormal uterine bleeding (AUB), painful rectal bleeding, hematuria
 - Shoulder tip pain, catamenial pneumothorax, cyclical cough/hemoptysis/chest pain
 - Cyclical scar swelling and
 - Chronic pain, fatigue [GPP].
- b. GDG recommended the use of symptom diary to objectify pain and empower women to demonstrate their symptoms [GPP].

Clinical Examination

- Women suspected of endometriosis should have a thorough vaginal examination.⁴ In adolescents and/or women without previous sexual intercourse, rectal examination has been advocated for the diagnosis of endometriosis [LE 4] [Grade A].
- Clinicians should rule out nonendometriotic causes in patients complaining of pelvic pain after thoroughly going through the findings of combination of history, physical examination, and imaging studies.⁵
- Clinicians should consider the diagnosis of deep endometriosis in women with (painful) indurations and/or nodules of the rectovaginal wall found during clinical examination, or visible vaginal nodules in the posterior vaginal fornix. It is best seen during menstruation⁶ [LE 4].
- Clinicians should suspect the presence of ovarian endometrioma in women if adnexal masses are detected during clinical examination [LE 3].
- Absence of clinical evidence during examination does not rule out the disease [LE 3].
- Further diagnostic steps including imaging are recommended even if clinical examination is normal [LE 2, Grade A].

Ultrasound

- Clinicians should recommend transvaginal ultrasound (USG) to diagnose or exclude ovarian endometrioma [LE 1].

- Transvaginal ultrasound should be done in a systematic way following the International Deep Endometriosis Analysis group (IDEA) consensus. It not only helps us to diagnose endometriosis but also helps us to stage the disease noninvasively, which aids us for surgical planning.⁷
- For ovarian endometriomas: transvaginal ultrasound showed good mean specificity and sensitivity with reasonable confidence intervals and heterogeneity [specificity 96%, 95% confidence interval (CI): 92–99%; sensitivity 93%, 95% CI: 87–99%].⁸
- In women with symptoms and signs of endometriosis, transvaginal sonography is useful for identifying rectal endometriosis. Probe tenderness may be elicited [LE 1].
- For deep endometriosis, with transvaginal ultrasound (including conventional ultrasound, 3-D ultrasound, and sonovaginography), overall specificity and sensitivity estimates have been reported as 94% and 79%, respectively, whereas sensitivity may be slightly improved with 3-D ultrasound (87%) [LE 1].⁷⁻⁹
- Clinicians should be aware that the usefulness of 3D USG to detect rectovaginal endometriosis is not well established [LE 4].
- Bladder endometriosis may be seen by transabdominal USG in clinically suspected cases. Hydronephrosis secondary to ureteric endometriosis may be detected by transabdominal USG. However, renal ultrasound is recommended in all patients with endometriosis to help rule out deep lesions.

Magnetic Resonance Imaging

- Magnetic resonance imaging (MRI) may detect small lesions more than 5 mm and helps distinguish endometrioma vs dermoid.
- Clinicians should be aware that peritoneal lesions will not be detected by MRI [LE 4].
- Clinicians should be aware that MRI can accurately detect rectovaginal disease and obliteration of pouch of Douglas (POD) in more than 90% of the cases.

Empirical Treatment

In women with clinical features suggestive of endometriosis, but with negative imaging, empirical medical treatment should be offered before invasive modalities.

Laparoscopy

- Only in patients with inconclusive imaging results or where empirical treatment was unsuccessful or inappropriate, the GDG recommends that clinicians consider offering laparoscopy for the diagnosis and treatment of suspected endometriosis.
- Tissue biopsy should be done, whenever possible, and negative biopsy does not rule out endometriosis [LE 1].
- Advances in the quality and availability of imaging modalities for at least some forms of endometriosis on the one hand and the operative risk, limited access to highly qualified surgeons, and financial implications on the other, calls for the urgent need for noninvasive modalities for diagnosis.
- Imaging combined with empirical treatment (hormonal pills or progestogens)/laparoscopy can be considered in the women suspected of endometriosis. There is no evidence of the superiority of either approach over the other and patients should be counseled about the pros and cons of each approach [GDG statement].
- Types of lesions on laparoscopy are powder burn or black lesions, white opacified peritoneum, glandular excrescences, flame-like red lesions, peritoneal pockets or windows, clear vesicles, yellow-brown patches, unexplained adherence of ovary to the peritoneum of ovarian fossa, encysted collection of thick chocolate colored or tarry fluids, adhesions to the posterior lip of broad ligaments or other pelvic structures [LE 1].

Biomarkers

- No biological markers currently exist that reliably can rule in and rule out endometriosis.
- Work on salivary micro-RNA shows promising results.
- CA-125 is not of much value in diagnosing the disease nor for follow-up. A negative CA-125 does not rule out the disease [LE 1].

Long Term Follow-up

Although there is currently no evidence of the benefit of regular long-term monitoring for the early detection of recurrence, complications or malignancy, it might help in improving the lives of affected women and in managing expectations and goals.

ADOLESCENT ENDOMETRIOSIS

Adolescent girls (13–19 years) constitute around 3–5% of the patients suffering from endometriosis. Among them, those who were suffering from chronic pelvic pain, 70% were reported to have endometriosis.¹⁰ The presenting features differ from adult population. Most of them present with severe dysmenorrhea and school absenteeism.¹¹ There are also difficulties in diagnosis as most of them present with atypical symptoms and are treated empirically. The diagnosis is often delayed in the adolescent girls for a period of more than 6–8 years if a high index of suspicion is not there.

- Endometriosis has to be suspected in adolescents when they have severe dysmenorrhea interfering with daily activities, chronic pelvic pain combined with nausea, dysuria, dyschezia, dyspareunia, and cyclical school absenteeism not responding to nonsteroidal anti-inflammatory drugs (NSAIDs) and oral contraceptive pills (OCPs), when taken for pain relief [LE 4, Grade A].
- Careful history taking for risk factor, such as positive family history of, obstructive genital malformations, early menarche, or short menstrual cycle, helps to suspect endometriosis in adolescents with cyclical and noncyclical chronic pelvic pain [LE 3, Grade A].
- Early-onset progressive dysmenorrhea in adolescents should be investigated for the possibility of Mullerian anomaly with outflow tract obstruction. [Evidence level GPP]
- Diagnosis in adolescents are through history, physical examination including vaginal examination after taking into consideration the acceptability, age and cultural background, risk factors, and family history combined with imaging technologies as the diagnostic accuracy of physical examination is low [LE 4].
- As transvaginal ultrasound is more effective in diagnosing endometriosis, it is used when appropriate, if not transabdominal, transrectal, and transperineal sonography can be done, and MRI only in selected cases. This may confirm diagnosis only in advanced lesions. Early lesions may not be picked out [LE 3, Grade A].
- Biomarkers CA-125 is not recommended for diagnosing or ruling out endometriosis. Work on other biomarkers, such as salivary micro-RNA, are still being validated [LE 2-Grade A].
- When the adolescents do not respond to NSAIDs, OCPs, and other hormonal treatments, diagnostic laparoscopy may be done to confirm the diagnosis as well as to treat [LE 3, Grade C].
- All forms of endometriosis have been found in laparoscopy and peritoneal diasese in adolescents may have atypical appearance.
- Positive histology confirms the diagnosis, even though negative histology does not exclude it [GPP].
- Expectant management for adolescent endometriosis, when it is diagnosed incidentally should be individualized [GPP].
- Continuous use of OCPs, low-dose OCP for adolescents is safe and effective for endometriosis-associated pelvic pain (EAPP) and can be used as the first line of treatment [LE 4, Grade A]. The use of OCPs will decrease the symptoms, but does not cause a decrease in the size of lesion.
- Progestins are also used for EAPP and have comparable results with that of gonadotropin hormone-releasing hormone (GnRH) analogues and danazol [LE 4].
- Newer progestins such as dienogest, help to relieve pain in adolescent girls and can be used for a longer period. The VISanne study to assess safety in ADOlescents (VISADO) study used dienogest for up to 52 weeks and has shown substantially reduced EAPP, mild reduction in lumbar bone mineral density (BMD) (1.2%), which improved partially after treatment discontinuation.
- GnRh agonists when used should have combined add-back therapy with both estrogen and progesterone. They are recommended only for girls beyond 18 years after a careful consideration and discussion of potential side effects and long-term health risks [LE 3, Grade C].
- When depot medroxyprogesterone acetate (DMPA) and GnRh are used, BMD reduction has to be monitored [LE 4]. Considering the possible side effects with regards to BMD and other long-term health risks, the GDG recommends

prescribing oral contraceptives or progestogens as the first line (Grade A), and GnRH agonist as the second-line treatment [Grade C].

- Levonorgestrel-releasing intrauterine system (LNG-IUS) can be used in sexually active adolescents as the first line of management¹² [LE 4, Grade A].
- Laparoscopy for endometriomas has to be balanced carefully, to avoid the loss of ovarian reserve vs pain relief [GPP].
- First surgery should be done by an experienced surgeon specialized in endometriosis, as adolescent endometriosis has atypical findings [GPP].
- Long-term postoperative hormone therapy should be considered and follow-up is must to prevent recurrence [LE 4, Grade A].
- Continuous OCPs can reduce the recurrence [LE 4, Grade A].
- Fertility preservation options exist. Adolescents and their families should be informed about that and can be considered in selected patients like bilateral ovarian endometriomas and those with unilateral ovarian surgery with contralateral ovarian recurrence as the true benefit remains uncertain for all.
- Trials on use of oral GnRH antagonist are on and results awaited.

ENDOMETRIOSIS AND INFERTILITY

The cause of infertility in women with endometriosis ranges from distortion in anatomy due to fibrosis and adhesions to endocrine abnormalities and immunological disturbances. The estimated overall prevalence of endometriosis in population-based studies varies from 0.8% to 6%;¹³ however, the prevalence seems to be higher in subfertile women ranging from 20% to 50%.¹⁴

Laparoscopy is no longer used as the first-line modality in the diagnosis of endometriosis. Transvaginal sonography (TVS) is the most ideal in diagnosing endometriosis and it should be done in a systematic way following the IDEA-CONSENSSES. MRI suggested as a complimentary investigation only if TVS is doubtful.

Are hormone or medical therapies effective for treatment of endometriosis-associated infertility?

- Ovarian suppression is not recommended in order to improve fertility in endometriosis women [LE 3, Grade A].
- Women those who are not willing to conceive immediately after surgery may be offered hormone therapy as it does not impair their fertility potential and improves the pain symptoms [LE 3, Grade C].

Is surgery effective to increase the chance of natural pregnancy?

- The decision to perform surgery should be guided by the presence or absence of pain symptoms, patient's age and preferences, history of previous surgery, presence of other infertility factors, ovarian reserve [anti-müllerian hormone (AMH)], and, systematic evaluation through TVS (IDEA-CONSENSSES) [GPP].
- Clinicians should counsel women with endometrioma regarding the risks of reduced ovarian function after surgery and the possible loss of ovarian reserve.
- Operative laparoscopy may be considered for the treatment of endometrioma-associated infertility as it may increase their chance of spontaneous pregnancy although no proper comparative studies exist [LE 4, Grade C].
- Laparoscopic surgery was found to increase natural pregnancy rates in the revised American Society for Reproductive Medicine (rASRM) stage I/II endometriosis¹⁵ [LE 3, Grade C].
- In infertile woman with the American Fertility Society (AFS)/ASRM stage III/IV endometriosis, clinicians can consider operative laparoscopy, instead of expectant management, to increase spontaneous pregnancy rates. The decision to proceed with surgery should be considered carefully if the woman has had previous ovarian surgery [LE 2].
- In infertile women with ovarian endometrioma undergoing surgery, clinicians should perform the excision of the endometrioma capsule, instead of the drainage and electrocoagulation of the endometrioma wall, to increase spontaneous pregnancy rates and decrease recurrence rates and pain [LE 3, Grade A].
- Surgery is not routinely recommended prior to assisted reproductive technology (ART), as it is likely to reduce ovarian reserve, response to ovarian stimulation is lower, higher gonadotropins usage in ART cycle and less number oocytes retrieved.

- Surgery prior to ART is only considered in the case of severe pain or nonaccessibility of follicles, rapid growth of the cyst, suspicious features on USG, potential for rupture during pregnancy.
- Do not remove uncomplicated deep endometriotic lesions in asymptomatic women, and also in symptomatic women not seeking conception when medical treatment is effective and well tolerated.

Which patients need treatment with assisted reproduction technology after surgery?

- Women should be counseled of their chances of becoming pregnant after surgery. To identify patients that may benefit from ART after surgery is important. If there is an extensive distortion of the anatomy, then ART should be recommended. The results of other fertility parameters, such as patient's AMH and their partner's sperm analysis, should be taken into account.
- The Endometriosis Fertility Index (EFI) was developed as an end of surgery scoring system, which predicts non-ART pregnancy rates after surgery. Patient-related factors (age, duration of infertility, and history of prior pregnancy) and surgical factors (least functional score of tubes and ovaries, endometriosis lesion and total score for rASRM staging) were scored. A score between 0 and 10 was generated. More the score, more is the chance of spontaneous pregnancy after surgery; hence, patients with very low EFI score (0–3) can be offered early ART [LE 3, Grade C].

Which patients with endometriosis require IVF/ICSI?

Diminished ovarian reserve, advanced maternal age, infertility of long duration, failed IUI cycles, recurrent endometriomas, associated tubal factor, male factor infertility, moderate to severe endometriosis in women >35 years.

Which stimulation protocol is ideal for women with endometriosis ?

- The extended administration of GnRH agonist prior to ART treatment to improve live birth rate in infertile women with endometriosis is not recommended, as the benefit is uncertain [LE 4, Grade A].
- Both GnRH antagonist and agonist protocols can be offered based on patients ovarian reserve [AMH, antral follicle count (AFC)] and physicians' preferences as there is no difference in pregnancy or live birth rates^{16,17} followed by downregulated frozen embryo transfer (FET) [LE 4, Grade C].
- The recurrence rates of endometriosis are not increased in women undergoing ART compared to those who are not undergoing ART [LE 2, Grade C].
- Antibiotic prophylaxis at the time of oocyte retrieval can be considered in women with endometrioma, although the risk of ovarian abscess formation following follicle aspiration is low¹⁸ [GPP].

MEDICAL MANAGEMENT OF ENDOMETRIOSIS

Medical management forms the cornerstone of treatment of endometriosis. Since endometriosis is a chronic progressive disease, it requires a long-term management plan for patients. There is an ongoing effort to limit the number of surgeries in patients with endometriosis.

Medical management is the treatment of choice for the treatment of symptomatic patients, who are not planning an immediate pregnancy. It should also be used postoperatively in patients who do not desire immediate pregnancy, to delay the progression of disease and prevent recurrence, if possible. It can also be used for recurrent disease with no suspicion of malignancy.

Medical management can be started empirically without the need of a definitive diagnosis.¹⁹ In creating a medical treatment plan, one must consider the symptoms, age of the patient, anatomic location of disease, severity, fertility requirement, the risks and benefits of both medical and surgical treatment, the various medical options available, cost, side effects, compliance, and patient's choice. It should be a shared decision, with the patient with treatment individually tailored, specific to that patient at that point of time.

The various medical options that are available are:

- NSAIDs
- Oral contraceptives
- Progestins
- Specially formulated progestin – Dienogest
- GnRH agonist
- GnRH antagonist
- Aromatase inhibitors
- Antiangiogenic drugs

Nonsteroidal Anti-Inflammatory Drugs

NSAIDs can be considered either alone or in combination with other treatments to relieve dysmenorrhea associated with endometriosis, and they have no effect on the long-term progression of disease²⁰ [LE 4, Grade C].

Combined Oral Contraceptive Pills

- Most guidelines support the use of OCP in the treatment of endometriosis related pain. Recent studies show the use of OCP is associated with decrease in dysmenorrhea, dyspareunia, cyclical nonmenstrual pain, and dyschezia resulting in improved quality of life^{21,22} [LE 2, Grade A].
- Combined oral contraceptives (COCs) act by the suppression of ovaries and by causing decidualization followed by the atrophy of the endometriotic tissue.
- The use of continuous OCP is better than cyclical OCP use for endometriosis-associated dysmenorrhea. It appears to be more effective for dysmenorrhea recurrence and is associated with a lower rate of cyst formation. There is no difference in the safety profile of continuous OCP use and standard cyclical OCP use. Continuous OCP can be offered in patients looking for amenorrhea [LE 3, Grade C].
- There is no specific recommendation of one OCP over the other. Any OCP can be used. The route of administration may be oral, vaginal, or transdermal [LE 3, Grade A].
- OCPs are cheap, easily available, safe, provide contraception and, hence, seem to score over other treatment options.
- However, the establishment and growth of endometriotic tissue is estrogen dependent and this still remains a point of concern for some. In some patients, COCs are contraindicated, such as age >35 years, smokers, history of thrombosis, etc.
- COCs are effective in pain management, but do not suppress disease or stop the progression of disease.
- They are considered as the first-line treatment in adolescents.
- Combination contraceptive with ethinyloestradiol and dienogest are also available, although it remains to be seen if they provide any additional benefit in the setting of endometriosis.

Progestins

- Progesterones are safe and effective treatment for endometriosis-associated pain. They can be considered as the first-line treatment option in the medical management of endometriosis [Grade A].
- There are many progesterones which are being used in the treatment of endometriosis such as medroxy progesterone acetate, cytoproterone acetate, norethindrone/norethisterone acetate, desogestrel, and dienogest.
- At the moment, there are no studies to prove the superiority of one progesterone over the other.
- Various side effects have been reported with different progestins – headache, bloating, weight gain, irregular bleeding, acne, depression, etc. The side effect profile of different progestins must be taken into account while recommending these molecules [GPP].

Dienogest

- Dienogest is a progestin that combines the properties of both 19 testosterone derivatives and progesterone derivatives.
- Given in the dose of 2 mg, it has been shown to reduce endometriosis-associated pain and improve the quality of life. It is as effective as GnRH agonist, but with much less side effects.
- It acts centrally by inhibiting gonadotropin secretion, suppressing circulating estradiol, causes anovulation and has local antiproliferative, anti-inflammatory, and antiangiogenic effects
- There have been studies where dienogest has been used for 52 weeks and has been shown to be effective [LE 3].
- Various side effects have been reported with dienogest such as vaginal bleeding, constipation, headache, nausea, and hot flushes.
- In adolescents, dienogest is associated with decrease in lumbar spine density with partial recovery on discontinuation. Hence, it should be used with caution.
- Dienogest has been shown to be safe and effective treatment for endometriosis and can be used on a long-term basis. However, it is expensive, availability may be an issue, and should be used with caution in adolescents.

Levonorgestrel-Releasing Intrauterine System

- Levonorgestrel-releasing intrauterine system (LNG-IUS) has a local effect on the ectopic endometrium as well as a direct effect on eutopic endometrium. It may also cause a reduction in local vascular angiogenesis.
- LNG-IUS has been shown to reduce endometriosis-associated pain and various studies have shown it to be as effective as GnRh agonist LE 2, Grade A].
- A lower recurrence rate has also been reported following the insertion of LNG-IUS postoperatively.
- Frequent side effects reported are spotting, one-sided abdominal pain, and simple ovarian cysts.
- The European Society of Human Reproduction and Embryology (ESHRE) guidelines recommend the postoperative use of LNG-IUS for at least 18–24 months as one of the options for the secondary prevention of endometriosis-associated dysmenorrhea, but not for nonmenstrual pelvic pain or dyspareunia.
- In patients not desiring fertility, it can be used for long-term.

Gonadotropin-Releasing Hormone Agonist

Mechanism of Action

- Initially, the GnRH agonist stimulate the pituitary resulting in an increased secretion of luteinizing hormone (LH) and follicle-stimulating hormone (FSH). However, long-term treatment will lead to the downregulation of GnRH receptors resulting in a decreased secretion of LH and FSH. This fall results in the suppression of follicular growth, resulting in the decreased levels of estrogen and progesterone.
- GnRH agonists may also have direct effect on the endometrium.

Side effects

- The circulating estradiol falls to about 15 pg/mL resulting in menopausal symptoms such as vasomotor symptoms, hot flashes, sleep disturbance, and urogenital atrophy.
- The ASRM and ESHRE both recommend to give add-back therapy with GnRh agonist treatment for patients with endometriosis-related pelvic pain (ERPP) to prevent bone loss and other hypoestrogenic symptoms [LE 2, Grade A].

Dosage schedules

- Inj Depot GnRH agonist monthly + norethindrone acetate 5 mg orally daily.
- Inj Depot GnRH agonist monthly + CEE 0.625 mg/1.25 mg + norethindrone acetate 5 mg orally daily.
Daily calcium supplement 1000 mg should be given to all the patients.

Points to be noted

- All regimens have similar reduction in pelvic pain.
- Add-back therapy reduces the incidence of vasomotor symptoms and helps preserve bone density. The ASRM and ESHRE both recommend starting the add-back therapy at the same time as GnRH agonist. The side effects of add-back therapy are minimal and may include spotting, bloating, and breast tenderness.
- Progestin-only add back is recommended as the addition of estrogen can result in the growth of endometriotic implants. However, a few patients may have severe symptoms, such as mood changes, weight gain, etc. in whom a low dose of conjugated equine estrogen (CEE) can be added.
- GnRH agonists are effective in reducing endometriosis associated pain; however, they can be used only for a limited time. They should not be used in adolescents because of loss of bone mineral density [Grade A].
- They can be prescribed as the second-line treatment [GPP].
- After initial GnRh agonist therapy, the patient can be given dienogest 2 mg daily/continuous oral contraceptives/LNG-IUS.
- In women in whom there is suboptimal relief of pain, aromatase inhibitors can be added [LE 3, Grade A].

Oral Gonadotropin-Releasing Hormone Antagonist

The oral GnRH antagonists can be prescribed as the second-line treatment, for ERPP. Their dosage and duration are uncertain. Most common side effects are hypoestrogenism [GPP].

Aromatase Inhibitors

- Aromatase converts androgens into estrogens. The primary sources of aromatase are ovarian granulosa cells in premenopausal women and adipose cells in postmenopausal women. Aromatase inhibitors suppress estrogen synthesis in the ovaries and in peripheral tissue.
- Anastrozole and letrozole are the third-generation aromatase inhibitors.
- Aromatase inhibitors reduce endometriosis-associated pain, intestinal symptoms, urinary symptoms, and decrease the volume of laparoscopically visible endometriosis, rectovaginal infiltrating endometriosis, and endometriomas.
- Endometriosis can affect about 2–5% of postmenopausal patients. In this group, aromatase inhibitors seem to be a possible medical treatment as the largest amount of estrogens is produced from extraovarian sources.
- Long-term use is associated with hypoestrogenic side effects. Hence, it should be used with add-back therapy.
- The ESHRE guidelines recommend the concomitant use of aromatase inhibitors and oral contraceptives, progesterones, or GnRH α in patients with pain associated with drug-resistant and surgery-resistant rectovaginal endometriosis. They can be used as second-line of therapy [LE 3, Grade A].
- The National Institute for Health and Care Excellence (NICE) and German society guidelines do not refer aromatase inhibitors as a possible endometriosis treatment. All the other societies agree that it could be a second-line therapy for endometriosis-associated pain reduction, although the evidence is not enough. The ASRM guidelines statement is that the above therapy should not be considered as a definitive therapy, as it is not the Food and Drug Administration (FDA) approved for endometriosis.

Antiangiogenic Drugs

Endometriosis has a multifactorial origin and neoangiogenesis is one of them. Antiangiogenic drugs act by exerting antiangiogenic effect by the inactivation of vascular endothelial growth factor receptor-2 (VEGFR-2). Cabergoline is the only drug option in endometriosis, which does not result in contraception.

Newer therapies

- Selective estrogen receptor modulator
- Anti-tumor necrosis factor (TNF).

SURGICAL MANAGEMENT OF ENDOMETRIOSIS

In the past, the diagnosis of endometriosis was almost always associated with surgery. Recently, in an effort to limit the number of surgeries in a particular patient, there has been a shift in the management of endometriosis towards medical management. However, surgery in endometriosis remains the definitive diagnostic and treatment approach.

Since endometriosis is a recurrent disease with an inherent set of surgical complications, the decision to take up the patient for surgery should be carefully considered.

The newer guidelines²⁰ give us a framework for when to operate a patient of endometriosis, namely:

- Failure/noncompliance/intolerance of medical management
- Incapacitating pain
- Severe and advanced disease with a significant anatomic distortion of pelvic organs and/or endometriomas
- Emergencies such as rupture of endometrioma, tubo-ovarian abscess, obstructive uropathy, and bowel obstruction
- Endometriosis-associated infertility [LE 3].

Preoperative Planning and Counseling

- The key to a successful surgery is meticulous pre-operative planning and proper counseling of the patient.
- Transparency and clear communication during the preoperative counseling process are essential and patients should be thoroughly educated about potential risks, such as reduced ovarian reserve, recurrence, the possibility of injury to adjacent organs, infection, the potential need for conversion to laparotomy, and the requirement for postoperative medical treatment. A written informed consent should be obtained detailing the same.
- Each patient should be properly assessed prior to surgery by a thorough physical examination and the requisite investigations done. For e.g., apart from ultrasound, a pelvic MRI may be needed in selected cases, ovarian reserve tests

(AFC, AMH) in cases of infertility, etc. As far as possible, the surgeon should be clear as regards to the extent of surgery required.

- It is always recommended that endometriosis be operated by an expert in an appropriately equipped center. A multidisciplinary approach is preferred, especially in cases where one suspects severe adhesions or involvement of ureter, bladder, bowel, etc.

Surgical Treatment Options for Endometriosis²³

- The surgery can be conservative aimed at preserving fertility, ablation, or the excision of peritoneal implants, resection of deep infiltrating implants, and removal of endometriomas or hysterectomy, with or without oophorectomy, based on the specific needs of the patient. At each surgery, attempt should be made to treat all the visible lesions [LE 3, Grade C].
- The approach to surgery can be by laparoscopy or laparotomy. Laparoscopy is the gold standard and is preferable to laparotomy for diagnosing and treating endometriosis-associated pelvic pain and infertility.
- Laparotomy should be taken into consideration, when multiple complex procedures involving other organ structures are involved or if expertise for laparoscopy is not available.

Conservative Surgery²⁴

- Conservative surgery should be considered for young patients with infertility and/or pain. It is the first-line surgical option for most patients as it conserves fertility and hormone production and is less invasive.
- The aim of conservative surgery is the treatment of the endometrioma and ablation/excision of all visible endometriotic lesions, excision of adhesions to restore normal pelvic anatomy while preserving the uterus and ovarian tissue. The advantage of excision is that it also provides a sample for histopathology.
- In an endometrioma, cystectomy is preferred over drainage and coagulation [LE 3, Grade A].
- Unilateral oophorectomy can be considered in a woman who has completed the family.

Points to ponder in cases of Infertility

- Avoid the excessive resection of ovarian tissue as it decreases the ovarian reserve.
- Avoid repeat surgery as it results in decreased ovarian reserve and should be recommended only when the patient is not responding to medical management or where malignancy is suspected. Repeat surgery results in a 50% reduction in pregnancy rates compared to the primary surgery.
- Egg freezing/embryo freezing prior to surgery can be discussed with the patient.
- Postoperative pregnancy rates in the rASRM stage III/IV cases range from 30% to 67%. The main benefit is observed within 6–12 months after surgery, but severe periovarian adhesions may recur and limit ovum pick-up. Hence, there should be a clear post operative plan for fertility in such cases [Grade C].
- Decision for surgery prior to in vitro fertilization (IVF) to be taken in cases where there is difficulty to access follicles at oocyte retrieval for endometriomas, fear of malignancy, rupture of cyst, and severe pain [GPP].
- The decision between repeat surgery and IVF should be based on age, ovarian reserve, symptoms, male factor infertility, and the presence of complex cysts needing histological diagnosis and the availability of skilled surgeons, and well-equipped setup.
- ART is more effective than repeat surgery in patients who failed to conceive spontaneously after surgery.

Surgical Consideration for Conservative Surgery for Pain in Endometriosis

- Shared decision making while choosing between hormone and surgical treatments for endometriosis pain should be done [GPP].
- Excision is preferred over ablation for reducing endometriosis-associated pain [LE 3, Grade C].
- All visible lesions should be treated and proper adhesiolysis done.
- Organ damage, fibrosis, and adhesions in advanced stages warrant surgical intervention for pain relief [LE 3, Grade A].
- Postoperative LNG-IUS/hormonal therapy for at least 18–24 months should be considered to prevent recurrence [LE 4, Grade A].

Hysterectomy

- Hysterectomy is indicated where a woman has adenomyosis or heavy menstrual bleeding that has not responded to other treatments.
- Women should be informed that a hysterectomy will not necessarily relieve the symptoms or cure the disease.²⁵
- The patient should be counseled regarding the risks and benefits of oophorectomy. In the case of ovarian conservation, the high recurrence rate should be discussed with the patient. If ovaries are removed, the consequences of early menopause and implications with respect to hormone replacement therapy (HRT) should be explained to the patient [GPP].

Deep Infiltrating Endometriosis²⁶

The surgical removal of deep endometriosis reduces endometriosis-associated pelvic pain and improves the quality of life. However, due to potential complications, it should be done at a center of expertise with multidisciplinary approach [GPP].

- The decision to offer the surgical excision of deep endometriosis lesions prior to ART should be guided by pain symptoms and patient's preference as its effectiveness on reproductive outcome is uncertain due to the lack of randomized studies. However, a few studies have shown skilled surgical management for symptomatic large deep infiltrating endometriosis (DIE) nodules infiltrating the rectum in young women is followed by a high pregnancy rate up to 4 years after surgery.
- It is recommended that discoid resection should be the first choice in rectal endometriosis patients with unifocal endometriotic lesions less than 3 cm, while segmental resection should be chosen in high bowel lesions, and when the discoid resection is not feasible.

Adjunct Surgical Intervention²⁷

- Laparoscopic uterosacral nerve ablation (LUNA) for the management of dysmenorrhea is not recommended as an additional procedure to conservative surgery to reduce endometriosis-associated pelvic pain expertise [GPP].
- Presacral neurectomy (PSN) is an effective additional procedure to conservative surgery to reduce mid-line pain, but requires high degree of skill and is potentially hazardous procedure with side effects such as bladder and bowel disturbances [GPP].

ADENOMYOSIS

Introduction

Adenomyosis is defined as the abnormal implantation of endometrial tissue into the myometrium associated with enlarging of the uterus. The exact etiology of adenomyosis remains unclear with some theories suggesting the invagination of the endometrium into the myometrium and others favoring metaplasia of stem cells. The disease is no longer considered typical of women over 40 years of age and around 30% of young women are affected by adenomyosis.

Symptoms

Common symptoms include pelvic pain (in the forms of dysmenorrhea, dyspareunia, and chronic pelvic pain), AUB, and impaired reproductive potential - infertility and recurrent miscarriage, local pressure symptoms, bladder and gastrointestinal symptoms – dysuria and dyschezia.

Investigations

- Transvaginal ultrasound is the primary tool for the noninvasive diagnosis of adenomyosis (pooled sensitivities and pooled specificities are 0.72–0.82, 0.85–0.81) [LE 2].²⁸
 - uterine enlargement
 - asymmetry of anterior and posterior uterine wall thickness
 - presence of hyperechogenic islands
 - translesional vascularity

- anechoic areas in the myometrium (known as myometrial cysts)
- myometrium with fan-shaped shadowing
- subendometrial echogenic lines and buds
- interrupted and irregular junctional zone (JZ)
- poor definition and thickening of the JZ.
- 3D transvaginal ultrasound (TVS) helps us to detect the lesions of adenomyosis.
- MRI is a complementary tool (pooled sensitivity of 0.77, specificity of 0.89) preferred in women when enlarged uterus is associated with other pathologies such as fibroids, endometriosis; when planning for conservative surgery, not willing for transvaginal scan, or when transvaginal scan is inconclusive [GPP].

Treatment

The aim of treatment is a life-long relief of symptoms and preserving fertility when required with minimal side effects. With more and more younger women being diagnosed with adenomyosis, noninvasive and less invasive management must be considered [GPP].

Medical Management

- The first line of treatment for adenomyosis. Medical therapy helps women to be relieved of their symptoms while preserving fertility. However, it provides only temporary relief requiring continuous management.
- NSAIDs can be used for pain relief in women planning for pregnancy [GPP].
- COCs are found to improve pain scores and menorrhagia to a limited extent with no effect on volume reduction.
- LNG-IUS and dienogest are found to be more efficacious than COC. With COC, the risk of thromboembolism should also be taken into consideration [LE 2].
- Dienogest can be given for long-term pain management and as postoperative maintenance treatment. The common adverse event reported is metrorrhagia [LE 3].^{29,30}
- LNG-IUS successfully relieves menorrhagia, dysmenorrhea and chronic pelvis pain in women with adenomyosis. It is a helpful modality for long-term management. Its role in volume reduction is limited and is seen 2 years postinsertion. LNG-IUS is a valid alternative for hysterectomy in perimenopausal women with an improved quality of life [LE 2].
- Women with larger volume uterus are associated with increased expulsion rate. To reduce the expulsion rates, GnRH agonist can be given to women with large uteri as pretreatment before LNG-IUS insertion to decrease uterine volume [LE 2].³²
- GnRH agonists are recommended in the treatment of adenomyosis as they reduce pain symptoms, bleeding, and uterine volume. However, the duration of use should be restricted to 3–6 months and supplemented with add-back therapy [LE 2].
- GnRH antagonist provides promising oral alternative to GnRH agonist with dose-related effects. Further studies are warranted for its use in clinical practise.
- Aromatase inhibitors 2.5–5 mg per day with add-back therapy can be used as an oral alternative to GnRH analogues in adenomyosis. It provides comparable efficacy in improving pain and bleeding symptoms and reduces the progression of disease. The combined therapy of aromatase inhibitor and GnRH agonists provides greater uterine volume reduction and better outcomes in refractory and large adenomyosis [LE 3].
- Danazol given locally via vaginal and intrauterine route seems to be effective for relieving pain and menorrhagia with also the advantage of volume reduction and avoiding systemic side effects. However, its use is restricted until further strong evidence is available.
- High intensity focused ultrasound (HIFU)/magnetic resonance-guided focused ultrasound (MRGFUS) are less invasive treatment modalities with limitations in patient selection for relief of dysmenorrhea and menorrhagia, but help preserve fertility. More randomized controlled trials (RCTs) are required to establish their safety in preserving fertility [LE 4].
- Uterine artery embolization (UAE) can be provided as an alternative to women who have completed child-bearing, in whom conservative management has failed, as a less invasive treatment alternative to hysterectomy. Long-term studies have confirmed it is an effective option in 80% of women and hysterectomy can be avoided in 90% of women [LE 2].

Surgical Management of Adenomyosis

- Uterus-sparing surgical approaches were developed for the treatment of adenomyosis. These methods are primarily based on the principle of removing the diseased tissue to decrease uterine size and improve clinical symptoms. Indications for conservative surgical management [LE 2].
 - Infertility - recurrent implantation failure and recurrent miscarriage not responding to medical management
 - Focal adenomyoma larger than 5 cm
 - AUB and dysmenorrhea refractory to medications desirous of preserving fertility.
- The mode of surgery can be laparoscopy or laparotomy and can be individualized. No particular technique has been shown to be superior.
- Laparotomy may be the preferred approach for some patients as it gives a better tactile recognition of the disease and secured opposition of the flaps. Laparoscopy may be preferred in well delimited and focal adenomyomas.
- As adenomyoma does not have a well-defined capsule, it may be difficult to demark the affected area. While wide resection is the aim, an attempt should be made to minimize the removal of normal tissue. Meticulous suturing is recommended to minimize dead space. Blood loss should be minimized by temporary uterine artery occlusion techniques and/or medications.
- Surgery can be associated with complications during pregnancy such as uterine rupture and placenta accreta syndrome. Pregnancy should not be planned for at least 3–6 months postsurgery.
- Hysterectomy is the preferred surgery in perimenopausal age group.
- Recurrence rates are lesser when postoperative medical therapy is prescribed [LE 3].
- Preoperative GnRH:
 - May reduce the size, vascularity and blood loss during surgery.
 - This facilitates laparoscopy rather than laparotomy.
 - Sometimes, during surgery, there may be difficulty in delineating the margins and complete excision may be difficult [LE 3].

Infertility and Pregnancy

- Should be individualized
- ART protocols antagonist/luteal agonist with vitrification of embryos followed by the a long GnRH agonist suppression of adenomyosis before frozen-thawed embryo transfer yields good fertility outcomes^{31,32}
- Women with repeated implantation failure (RIF) should be screened for adenomyosis.

Adenomyosis and Pregnancy

- Awareness of the adverse effects of adenomyosis on pregnancy such as miscarriage, preterm delivery, placental disorders such as hypertensive disorders in pregnancy and pre-eclampsia, FGR, malposition, and postpartum hemorrhage make it necessary to screen, diagnose early and manage the pregnancy complications appropriately [LE 2].³⁴
- Women with adenomyosis should be counseled prior to conception about the effects of adenomyosis on fertility and obstetric outcomes [GPP].

SCAR ENDOMETRIOSIS

- Abdominal wall endometriosis is commonly associated with gynecological procedures such as laparoscopy, cesarean section, appendicectomy, or abdominal hysterectomy [LE 4].³³⁻³⁵
- The average time period between the index surgery and the clinical presentation of abdominal wall endometriosis was 3.6 years.³⁶
- Cesarean scar endometriosis(CSE) is the most common type of abdominal wall endometriosis with the incidence of 0.03–1.5%
- Episiotomy endometriosis is even less common (0.01%–0.06%).

Symptoms and diagnosis	<ul style="list-style-type: none"> Clinicians should be aware that cyclical changes of size and intensity of pain noted during menstruation over the implant points towards scar endometriosis (GPP) 20-70% patients present with cyclical symptoms of tenderness on palpation. Hypertrophic and hyperpigmented scars due to hemosiderin deposits are seen [LE 2]
Management	<ul style="list-style-type: none"> For abdominal extrapelvic endometriosis, surgical removal is the preferred treatment when possible, to relieve symptoms. Hormone treatment may also be an option when surgery is not possible or acceptable [LE 3, Strong recommendation] Therapeutic management is essentially based on a wide surgical excision, with clear margins and the reconstruction of damaged tissue³⁷ Hormonal treatment, such as progestins, OCPs, danazol, GnRH agonist, and dienogest, can be used, but it gives only partial pain relief in scar endometriosis. There will be recurrence after the cessation of the drug and it do not have any effect on the size of lesion³⁸

- Recurrence after the surgical removal of the scar endometriotic lesion was reported to be 4.3%.³⁸
- Preventive measures: Excluding the decidua while closing the uterus, using different mops and needles for different layers, careful flushing and irrigation of the adipose layer and fascia layer during closure, and isolation of surgical incision site, instrument, and needles [GPP].

ENDOMETRIOSIS AND MALIGNANCY

- Endometriosis is a chronic inflammatory disorder. Some of the endometriotic lesions undergo somatic mutations, which leads to malignant transformation. Hence, identification of high-risk endometriotic lesions and their appropriate management is essential for the successful prediction and outcomes of endometriosis-associated ovarian cancer (EAOC).
- Overall endometriosis is associated with a very small and not a statistically significant increased risk of cancer³⁹ [LE 2].
- The relative risk of developing ovarian cancer in endometriosis has been reported to be 1.4–1.8 in various studies⁴⁰⁻⁴² [LE 2].
- Endometriosis is associated with a higher risk of ovarian cancer particularly-Clear cell odontogenic carcinoma (CCOC) and endometrioid histotypes, breast cancer, and thyroid cancer. No increased risk of colorectal cancer and the lower risk of cervical cancer have been reported [LE 3, Grade A].

Absolute Risk of Women Developing Cancer in Life time

Cancer	All women	Women with endometriosis	Increase in risk in women with endometriosis
Ovarian cancer	1.3%	2.5%	+1.2%
Breast cancer	12.8%	13.3%	+0.5%
Thyroid cancer	1.3	1.8%	+0.5%

- Clinicians reassure women with endometriosis with regards to their cancer risk by recommending general cancer prevention measures (avoiding smoking, maintaining a healthy weight, exercising regularly, having a balanced diet with high intakes of fruits and vegetables and low intakes of alcohol, and using sun protection) [GPP].

Impact of hormone treatment

Clinicians should reassure women with endometriosis that the risks of ovarian, endometrial, and colorectal cancers are decreased in women who use OCP [LE 4, Grade A].

Screening for Malignancy in Endometriosis

Since there is only slight increase in the risk of ovarian cancer in endometriosis patients, routine screening by serum CA-125 or by TVS is not recommended, however, screening could be considered in high-risk individuals with strong family history/ specific germ line mutations [GPP].

Diagnosis of Ovarian Malignancy in Endometriosis

- USG (TVS) is the first line of investigation, where there will be increase in the size of cyst in postmenopausal women and those who are on hormonal therapy, appearance of vascularized solid component, presence of ascites, and other features suggestive of malignancy.
- MRI has high specificity and can be used as a complimentary to USG. It has the added advantage of mapping the complete extent of disease prior to surgery.⁴³

Surgery in Malignancy

- Surgical excision of endometriosis, from the ovaries and from other locations, may reduce the risk of subsequent ovarian cancer [LE 3, Grade A].
- Removal of the affected ovary, wherever appropriate, may have a bigger cancer risk reduction than the excision of disease and preservation of the ovary.
- If endometriosis involves both ovaries, bilateral salpingo-oophorectomy (BSO) should be considered with caution with regards to other long-term health risk (LE 4).

MENOPAUSE AND ENDOMETRIOSIS

Due to the steroid-dependent nature of endometriosis, there will be the regression of disease in most women after menopause. Still, quite a few number of women experience endometriosis-related symptoms after natural or surgical menopause. Women on hormone therapies aimed at relieving postmenopausal complaints may experience the worsening of symptoms and reactivation of residual disease.

The incidence of endometriosis in post menopausal women was estimated to range from 2% to 5%.⁴⁴⁻⁴⁶ The categories that need care, are the women who have menopausal symptoms due to surgical menopause after bilateral oophorectomy done for endometriosis, and the occurrence or progression of postmenopausal endometriosis.

Endometriosis in Postmenopausal Patients

- The first-line treatment for endometriosis in postmenopausal patients with pain should be surgical to enable histological diagnosis^{47,48} [LE 4, Grade C].
- The risk of malignant transformation should be kept in mind in women with endometriosis irrespective of symptoms, which may require further imaging studies; and if a pelvic mass is detected, the work-up and treatment should be performed according to the national oncology guidelines⁴⁹ [GPP].
- In case where surgery is not feasible or symptoms recur or persist after surgery, medical treatment may be indicated. Medical management (hormone therapies besides using analgesics or aromatase inhibitors) are limited in postmenopausal women compared to premenopausal due to low systemic estrogen levels) [LE 4, Grade C].
- Aromatase inhibitors act by blocking the extraovarian estrogen production, which is one of the important sources in postmenopausal women. Hence, aromatase inhibitors can be considered as treatment option in postmenopausal women, where surgery is not feasible [LE 4, Grade C].

Menopausal Symptoms in Women with Endometriosis

- Postmenopausal women with endometriosis-associated pain on menopausal hormone therapy (MHT), the first-line approach is to discontinue MHT while considering the likely recurrence of menopausal vasomotor symptoms.
- In postmenopausal women with vasomotor symptoms and urogenital atrophy following natural or surgical menopause, combined MHT is effective. Combined MHT should continue at least till the age of natural menopause⁵⁰ [IMS Recommendation]) [GPP].
- Estrogen-only therapies have a higher risk of malignant transformation⁵¹ [Evidence level low, Grade A].
- Tibolone, which has estrogenic effect on vasomotor symptom and bone yet a progestogenic like effect on endometrium, could be an alternative for combined MHT.⁵² But current evidences show a high risk of endometrial carcinoma than with combined MHT; therefore, this is not recommended⁵³ [LE 4].
- Role of phytoestrogens with both estrogenic and antiestrogenic effects in endometriosis, especially for long-term use has not been studied.

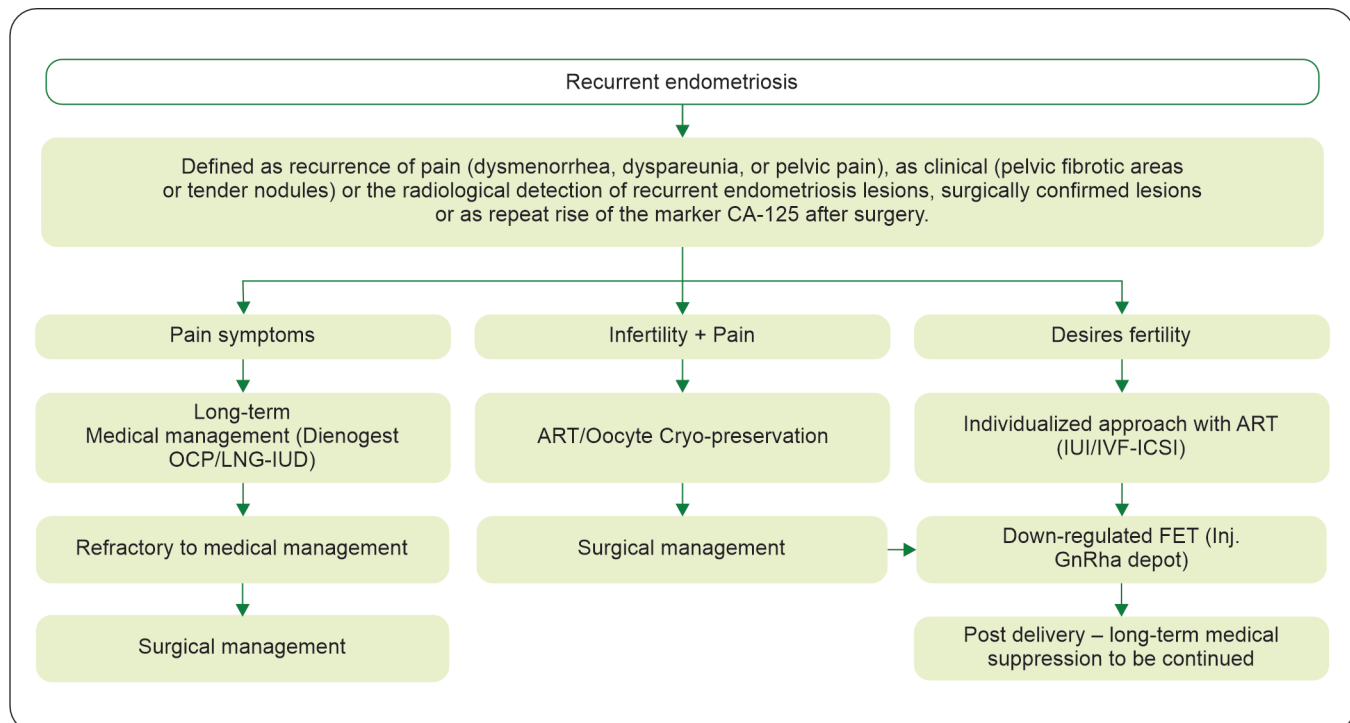
Menopause Related Major Health Concern

Women with endometriosis have an increased risk of cardiovascular disease; myocardial infarction [relative risk (RR): 1.52], angina (RR: 1.91), coronary surgery (RR: 1.35) or any of these coronary heart disease endpoints combined (RR: 1.62). About 42% of this association could be explained by a history of hysterectomy/BSO and earlier age at surgery. So, screening for cardiovascular disease, diet, lifestyle modifications are strongly recommended⁵⁴ [GPP].

FERTILITY PRESERVATION IN ENDOMETRIOSIS

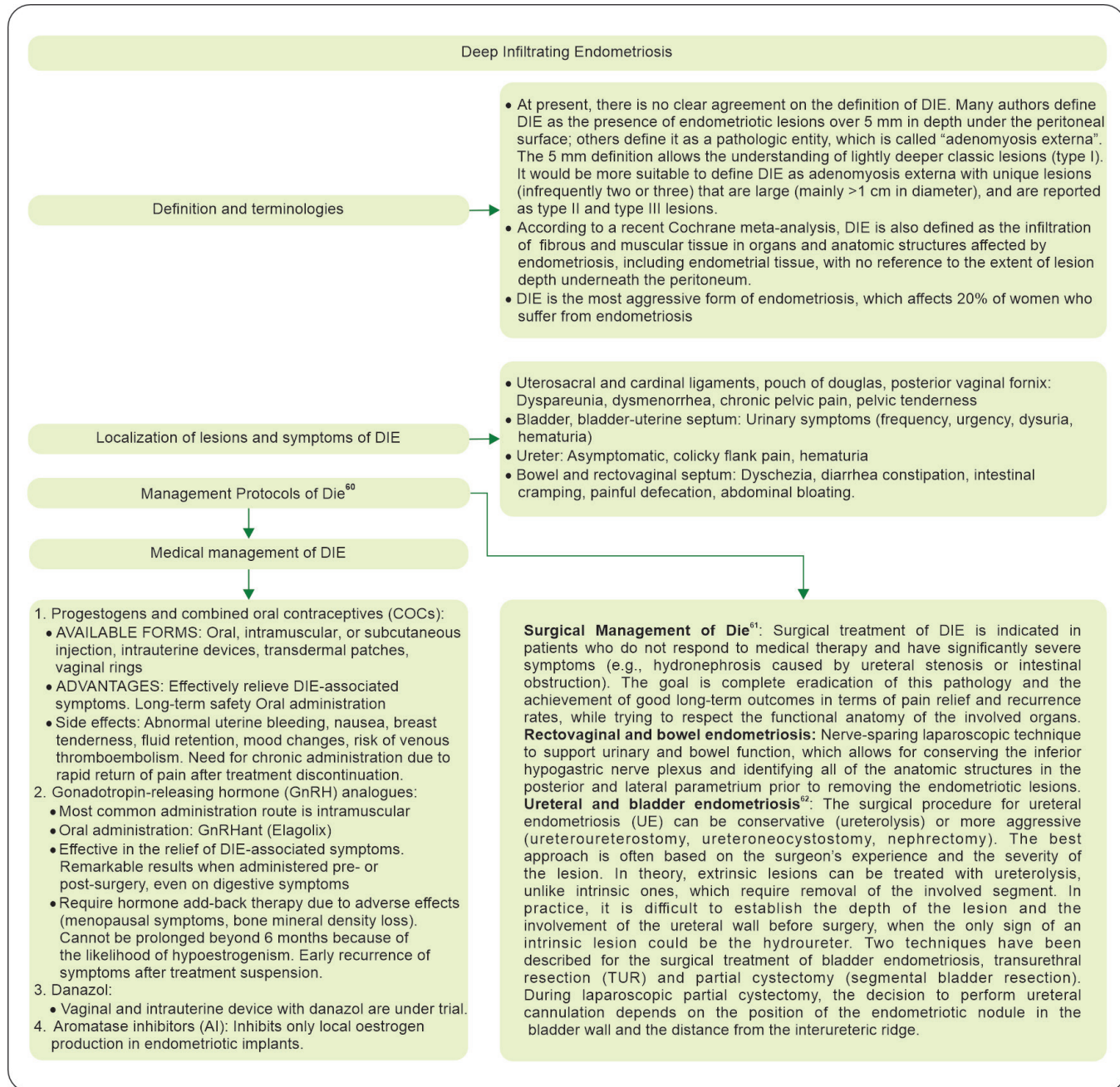- Women with severe endometriosis, especially with bilateral endometriomas are at an increased risk of ovarian insufficiency and lower AMH levels.
- There is rapid decline in the serum AMH levels per year in women with endometriosis compared to general population, 26.4% vs 7.4%, respectively.⁵⁵
- Women with endometriosis-related infertility or with a history of endometriosis are reported to experience menopause earlier than in women without endometriosis.^{56,57}
- Hence, women with endometriosis could be counseled about the rapid loss of their reproductive potential and urge to consider their childbearing plans.
- Fertility preservation is a valid treatment option in endometriosis.
- After oocyte cryopreservation, the oocyte survival rates are 83.2% and cumulative live birth rates are 46.4%.⁵⁸
- When women are not keen on ovarian stimulation or is not feasible, during surgery cryo preservation of ovarian cortical tissue can be considered.⁵⁹
- However, the benefits of cryopreservation in women with endometriosis is unknown [GPP].

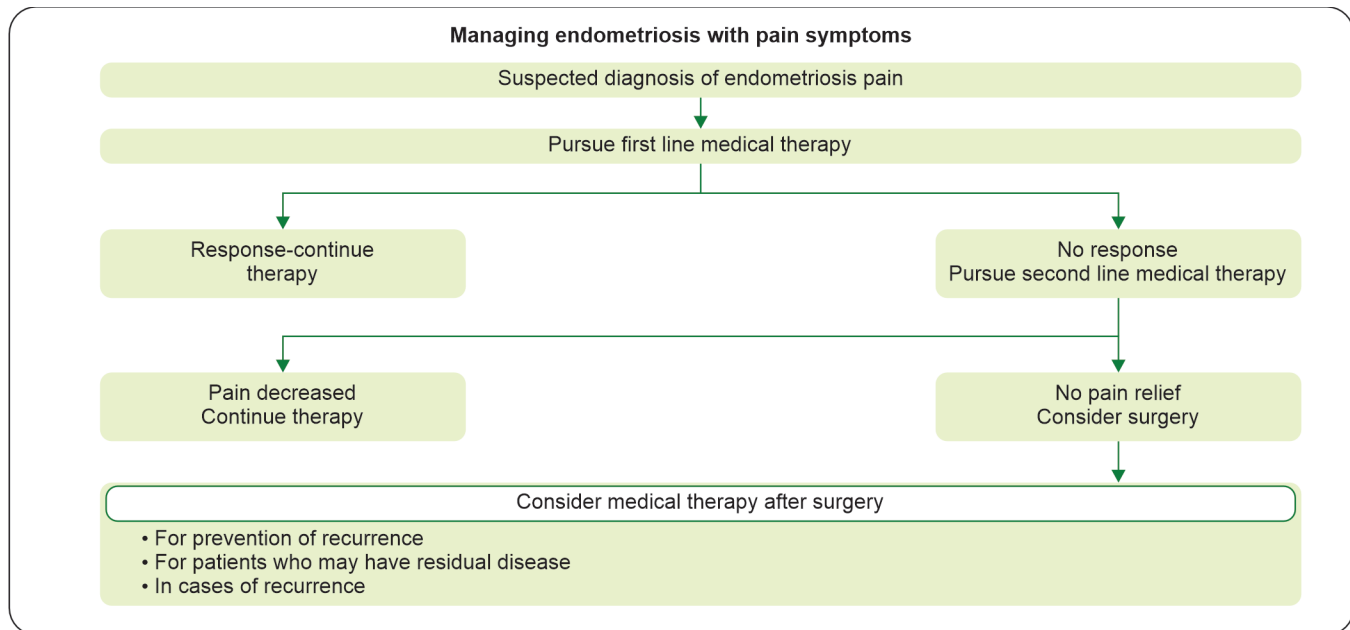
RECURRENT ENDOMETRIOSIS



Abbreviations: ART: Assisted reproductive technology; FET: Frozen embryo transfer; ICSI: Intracytoplasmic sperm injection; IUI: Intrauterine insemination; IVF: In vitro fertilization; LNG-IUD: Levonorgestrel-releasing intrauterine device; OCP: Oral contraceptive pill

DEEP INFILTRATING ENDOMETRIOSIS (DIE)





Medical management of endometriosis

Drug	Type	Special remarks	Side-effects
NSAID	Non hormonal	Symptomatic Does not stop disease progression	Gastric ulcer, renal disease, bronchospasm
COC	First line	Oral, vaginal, transdermal Continuous use preferred	VTE, nausea, vomiting
Progesterones	First line	Oral LNG IUS - ease of use, beneficial in dysmenorrhoea	Wt gain, breast tenderness, increase LDL levels
Dienogest	First line	Formulated for endometriosis Can be used for 52 weeks	Irregular bleeding, acne, nausea
GnRH agonist	Second line	Injectable Short term use Add back therapy recommended	BMD loss, VTE, Hot flushes
GnRH antagonist	Second line	Oral	Hot flushes, BMD loss
Aromatase inhibitor	Third line	Add back therapy recommended Can be used in drug resistant recto vaginal endometriosis Can be used in post menopausal patients	Arthralgia, myalgia, decreased BMD

REFERENCES

- Jenkins S, Olive DL, Haney AF. Endometriosis: pathogenetic implications of the anatomic distribution. *Obstet Gynecol.* 1986;67(3):335-8.
- Parasar P, Ozcan P, Terry KL. Endometriosis: epidemiology, diagnosis and clinical management. *Curr Obstet Gynecol Rep.* 2017;6(1):34-41.
- Eskenazi B, Warner ML. Epidemiology of endometriosis. *Obstet Gynecol Clin North Am.* 1997;24(2):235-58.
- Hsu AL, Khachikyan I, Stratton P. Invasive and noninvasive methods for the diagnosis of endometriosis. *Clin Obstet Gynecol.* 2010;53(2):413-9.
- Ahn SH, Monsanto SP, Miller C, et al. Pathophysiology and immune dysfunction in endometriosis. *Bio Med Res Int.* 2015;2015:795976.
- Koninckx PR, Martin DC. Deep endometriosis: a consequence of infiltration or retraction or possibly adenomyosis externa? *Fertil Steril.* 1992;58(5):924-8.

7. Guerriero S, Condous G, van den Bosch T, et al. Systematic approach to sonographic evaluation of the pelvis in women with suspected endometriosis, including terms, definitions and measurements: a consensus opinion from the International Deep Endometriosis Analysis (IDEA) group. *Ultrasound Obstet Gynecol.* 2016;48(3):318-32.
8. Nisenblatt V, Bossuyt PMM, Farquhar C, et al. Imaging modalities for the non-invasive diagnosis of endometriosis. *Cochrane Database Syst Rev.* 2016;2(2):CD009591.
9. Keckstein J, Hoopmann M, Merz E, et al. Expert opinion on the use of transvaginal sonography for presurgical staging and classification of endometriosis. *Arch Gynecol Obstet.* 2023;307(1):5-19.
10. Laufer MR, Sanfilippo J, Rose G. Adolescent endometriosis: diagnosis and treatment approaches. *J Pediatr Adolesc Gynecol.* 2003;16(3 Suppl):S3-11.
11. Brosens I, Gordts S, Benagiano G. Endometriosis in adolescents is a hidden, progressive and severe disease that deserves attention, not just compassion. *Hum Reprod.* 2013;28(8):2026–31.
12. Abou-Setta AM, Al-Inany HG, Farquhar CM. Levonorgestrel-releasing intrauterine device (LNG-IUD) for symptomatic endometriosis following surgery. *Cochrane Database Syst Rev.* 2006;4(4):CD005072.
13. Abbas S, Ihle P, Köster I, et al. Prevalence and incidence of diagnosed endometriosis and risk of endometriosis in patients with endometriosis-related symptoms: findings from a statutory health insurance-based cohort in Germany. *Eur J Obstet Gynecol Reprod Biol.* 2012;160(1):79-83.
14. Meuleman C, Vandenabeele B, Fieuws S, et al. High prevalence of endometriosis in infertile women with normal ovulation and normospermic partners. *Fertil Steril.* 2009;92(1):68-74.
15. Bafort C, Beebejaun Y, Tomassetti C, et al. Laparoscopic surgery for endometriosis. *Cochrane Database Syst Rev.* 2020;10(10):CD011031.
16. Pabuccu R, Onalan G, Kaya C. GnRH agonist and antagonist protocols for stage I-II endometriosis and endometrioma in in vitro fertilization/intracytoplasmic sperm injection cycles. *Fertil Steril.* 2007;88(4):832-9.
17. Cao X, Chang H-Y, Xu J-Y, et al. The effectiveness of different down-regulating protocols on in vitro fertilization-embryo transfer in endometriosis: a meta-analysis. *Reprod Biol Endocrinol.* 2020 29;18(1):16.
18. Somigliana E, Vigano P, Benaglia L, et al. Ovarian stimulation and endometriosis progression or recurrence: a systematic review. *Reprod Biomed Online.* 2019;38(2):185-94.
19. Kim M-R, Chapron C, Römer T, et al. Clinical diagnosis and early medical management for endometriosis: consensus from Asian Expert Group. *Healthcare (Basel).* 2022;10(12):2515.
20. Becker CM, Bokor A, Heikinheimo O, et al. ESHRE guideline: endometriosis. *Hum Reprod Open.* 2022;2022(2):hoac009.
21. Jensen JT, Schlaff W, Gordon K. Use of combined hormonal contraceptives for the treatment of endometriosis-related pain: a systematic review of evidence. *Fertil Steril.* 2018;110(1):137-52.e1.
22. Grandi G, Barra F, Ferrero S, et al. Hormonal contraception in women with endometriosis: a systematic review. *Eur J Contracept Reprod Health Care.* 2019;24(1):61-70.
23. Johnson NP, Hummelshoj L; World Endometriosis Society Montpellier Consortium. Consensus on current management of endometriosis. *Hum Reprod.* 2013;28(6):1552-68.
24. Alborzi S, Momtahan M, Parsanezhad ME, et al. A prospective, randomized study comparing laparoscopic ovarian cystectomy versus fenestration and coagulation in patients with endometriomas. *Fertil Steril.* 2004;82(6):1633-7.
25. Rizk B, Fischer AS, Lotfy HA, et al. Recurrence of endometriosis after hysterectomy. *Facts Views Vis Obgyn.* 2014;6(4):219-27.
26. D'Alterio MN, D'Ancona G, Raslan M, et al. Management challenges of deep infiltrating endometriosis. *Int J Fertil Steril.* 2021;15(2):88-94.
27. Kalaitzopoulos DR, Samartzis N, Kolovos GN, et al. Treatment of endometriosis: a review with comparison of 8 guidelines. *BMC Women's Health.* 2021;21(1):397.
28. Harmsen MJ, Van den Bosch T, de Leeuw RA, et al. Consensus on revised definitions of Morphological Uterus Sonographic Assessment (MUSA) features of adenomyosis: results of modified Delphi procedure. *Ultrasound Obstet Gynecol.* 2022;60(1):118-31.
29. Osuga Y, Fujimoto-Okabe H, Hagino A. Evaluation of the efficacy and safety of dienogest in the treatment of painful symptoms in patients with adenomyosis: a randomized, double-blind, multicenter, placebo-controlled study. *Fertil Steril.* 2017;108(4):673-8.
30. Vannuccini S, Luisi S, Tosti C, et al. Role of medical therapy in the management of uterine adenomyosis. *Fertil Steril.* 2018;109(3):398-405.
31. Park CW, Choi MH, Yang KM, et al. Pregnancy rate in women with adenomyosis undergoing fresh or frozen embryo transfer cycles following gonadotropin-releasing hormone agonist treatment. *Clin Exp Reprod Med.* 2016;43(3):169-73.
32. Nirgianakis K, Kalaitzopoulos DR, Schwartz ASK, Spaanderman M, Kramer BW, Mueller MD, Mueller M. Fertility, pregnancy and neonatal outcomes of patients with adenomyosis: a systematic review and meta-analysis. *Reprod Biomed Online.* 2021;42(1):185-206.
33. Andres MP, Arcoverde FVL, Souza CCC, et al. Extrapelvic endometriosis: A systematic review. *J Minim Invasive Gynecol.* 2020;27(2):373-89.
34. Hirata T, Koga K, Kitade M, et al. A national survey of umbilical endometriosis in Japan. *J Minim Invasive Gynecol.* 2020;27(1):80-7.
35. Chamie LP, Ribeiro DMFR, Tiferes DA, et al. Atypical sites of deeply infiltrative endometriosis: Clinical characteristics and imaging findings. *Radiographics.* 2018;38(1):309-28.
36. Horton JD, Dezee KJ, Ahnfeldt EP, Wagner M. Abdominal wall endometriosis: a surgeon's perspective and review of 445 cases. *Am J Surg.* 2008;196(2):207–12.

37. Oh EM, Lee W-S, Kang JM, et al. A surgeon's perspective of abdominal wall endometriosis at a caesarean section incision: nine cases in a single institution. *Surg Res Pract*. 2014;2014:765372.
38. Al-Jabri K. Endometriosis at caesarian section scar. *Oman Med J*. 2009;24(4):294-5.
39. Kvaskoff M, Mahamat-Saleh Y, Farland LV, et al. Endometriosis and cancer: a systematic review and meta-analysis. *Hum Reprod Update*. 2021;27(2):393-420.
40. Pearce CL, Templeman C, Rossing MA, et al. Association between endometriosis and risk of histological subtypes of ovarian cancer: a pooled analysis of case-control studies. *Lancet Oncol*. 2012;13(4):385-94.
41. Kim HS, Kim TH, Chung HH, et al. Risk and prognosis of ovarian cancer in women with endometriosis: a meta-analysis. *Br J Cancer*. 2014;110(7):1878-90.
42. Saraswat L, Ayansina D, Cooper KG, et al. Impact of endometriosis on risk of further gynaecological surgery and cancer: a national cohort study. *BJOG*. 2018;125(1):64-72.
43. Kobayashi H. Ovarian cancer in endometriosis: epidemiology, natural history, and clinical diagnosis. *Int J Clin Oncol*. 2009;14(5):378-82.
44. Bendon CL, Becker CM. Potential mechanisms of postmenopausal endometriosis. *Maturitas*. 2012;72(3):214-9.
45. Polyzos NP, Fatemi HM, Zavos A, et al. Aromatase inhibitors in post-menopausal endometriosis. *Reprod Biol Endocrinol*. 2011;9:90.
46. Streuli I, Gaitzsch H, Wenger JM, et al. Endometriosis after menopause: physiopathology and management of an uncommon condition. *Climacteric*. 2017;20(2):138-43.
47. Oxholm D, Knudsen UB, Kryger-Baggesen N, et al. Postmenopausal endometriosis. *Acta Obstet Gynecol Scand*. 2007;86(10):1158-64.
48. Pavone ME, Bulun SE. Aromatase inhibitors for the treatment of endometriosis. *Fertil Steril*. 2012;98(6):1370-9.
49. Morotti M, Remorgida V, Venturini PL, et al. Endometriosis in menopause: a single institution experience. *Arch Gynecol Obstet*. 2012;286(6):1571-5.
50. Baber RJ, Panay N, Fenton A, et al. 2016 IMS Recommendations on women's midlife health and menopause hormone therapy. *Climacteric*. 2016;19(2):109-50.
51. Gemmell LC, Webster KE, Kirtley S, et al. The management of menopause in women with a history of endometriosis: a systematic review. *Hum Reprod Update*. 2017;23(4):481-500.
52. Sundar SS, Gornall RJ, Kerr-Wilson R, et al. A case report of recurrent endometriosis following Tibolone hormone replacement therapy. *J ObstetGynaecol*. 2007;27(4):433-4.
53. Løkkegaard ECL, Mørch LS. Tibolone and risk of gynecological hormone sensitive cancer. *Int J Cancer*. 2018;142(12):2435-40.
54. Mu F, Rich-Edwards J, Rimm EB, et al. Association between endometriosis and hypercholesterolemia or hypertension. *Hypertension*. 2017;70(1):59-65.
55. Kasapoglu I, Ata B, Uyaniklar O, et al. Endometrioma-related reduction in ovarian reserve (ERROR): a prospective longitudinal study. *FertilSteril*. 2018;110(1):122-7.
56. Yasui T, Hayashi K, Mizunuma H, et al. Association of endometriosis-related infertility with age at menopause. *Maturitas*. 2011;69(3):279-83.
57. Pokoradi AJ, Iversen L, Hannaford PC. Factors associated with age of onset and type of menopause in a cohort of UK women. *Am J Obstet Gynecol*. 2011;205(1):34.e1-13.
58. Cobo A, Giles J, Paoelli S, et al. Oocyte vitrification for fertility preservation in women with endometriosis: an observational study. *Fertil Steril*. 2020;113(4):836-44.
59. Donnez J, Garcia-Solares J, Dolmans M-M. Ovarian endometriosis and fertility preservation: a challenge in 2018. *Minerva Ginecol*. 2018;70(4):408-14.
60. Ugwumadu L, Chakrabarti R, Williams-Brown E, et al. The role of the multidisciplinary team in the management of deep infiltrating endometriosis. *Gynecol Surg*. 2017;14(1):15.
61. Chapron C, Chopin N, Borghese B, et al. Surgical management of deeply infiltrating endometriosis: an update. *Ann N Y Acad Sci*. 2004;1034:326-37.
62. Knabben L, Imboden S, Fellmann B, et al. Urinary tract endometriosis in patients with deep infiltrating endometriosis: prevalence, symptoms, management, and proposal for a new clinical classification. *Fertil Steril*. 2015;103(1):147-52.