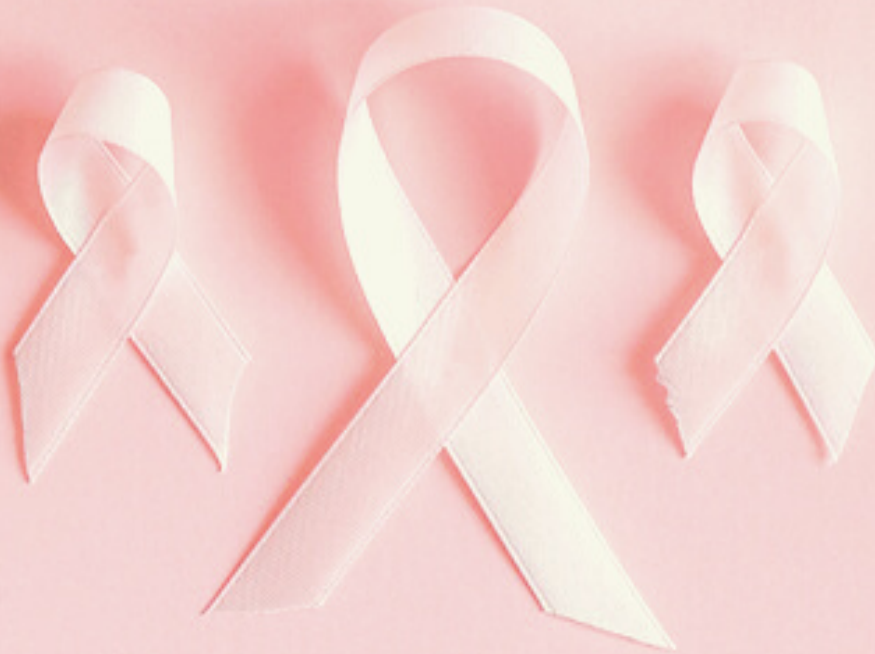

Breast Committee FOGSI



e-Newsletter
Diseases of the Breast

January 2021

Editors



Dr. Sneha S Bhuyar



Dr. Suchitra N Pandit



Dr. Parag Biniwale

Coordinators



Dr. Charulata Bapaye



Dr. Varsha Lahade

DETECT TO PROTECT



**A Female Breast
Diseases Committee
FOGSI Initiative**



PRESIDENT'S MESSAGE

“Attitude is a little thing that makes a big difference”

Winston Churchill.

Diseases of the breast, both benign and malignant, are dangerously common in our population. But for generations, women have suffered in silence because talking about them was something they considered shameful. Small lumps grew unchecked into massive tumours that caused debilitating illnesses and untimely deaths.

Two things have changed in recent years:

One- Our diagnostic abilities. We have better technology, from mammograms to genetic testing and everything in between, that help our practitioners pick up early stages of diseases and treat them effectively. We have advanced surgical techniques, and personalized chemotherapies that give us a targeted and individualized approach.

Second: Our awareness. Our patients today are a lot less afraid to talk about diseases of the breast. They are aware of the early signs and symptoms, they know basic self-care measures like self-examination, and the importance of things like breastfeeding.

Both these approaches together give us a much better chance of effectively treating our patients with breast diseases.

I congratulate Dr. Sneha Bhuyar, Chairperson, Breast committee, FOGSI and the team for publishing this newsletter on a topic that needs to come out of the shadows even more. This is definitely a step in the right direction. I wish you luck and success.



Dr. Alpesh Gandhi

President FOGSI 2020

Vice President's message

Dear Dr. Sneha S Bhuyar

It is my proud privilege to be in charge of breast committee and to be associated with you, a dynamic, dedicated person with out of the box thinking.



Your present endeavors are really needed and with you at helm of affairs, I know they will be of great help to all readers.

I wish you very best.

I am with you at each step.

Many many congratulations for this launch.

Thanks

Dr. Ragini Agrawal

**Vice President FOGSI 2020 &
Incharge Breast Committee**



Secretary General's message

My dear fellow FOGSIAN's

It is my pleasure and privilege to write this message.

The need to focus attention on Breast Cancer is self evident. That there is a problem is beyond doubt and although opinions on the way forward may differ, the destination is the same for anyone who is associated with caring for the women of our country.



I would like to congratulate the Chair of the Breast Committee Dr. Sneha S Bhuyar, the Editors - Dr. Suchitra Pandit & Dr. Parag Biniwale, the Coordinators- Dr. Charu lata Bapaye & Dr. Varsha Lahade, and the Guidance & Support from Dr. Ragini Agrawal VP In charge Breast Committee & Dr. T. Ramani Devi and all the writers of the newsletter.

This newsletter serves as a timely reminder of the matter at hand and helps in lighting a way to our destination. FOGSI advocates tirelessly both for the cause and its members and we recognize the need for more awareness and action on the issue.

Warm regards,

Dr. Jaydeep Tank

Secretary General FOGSI (2018 - 2021).



Editor's Desk

Dear Friends,

It gives us immense pleasure to present to you, e-news letter on Diseases of the Breast, Study of Female Breast Committee FOGSI, led by Dr. Sneha S Bhuyar.

Breast diseases are on the rise and most of the times; women approach Gynaecologists for diagnosis and treatment. Unfortunately, in most of the medical colleges, breast diseases are managed by General surgeons and Gynaecology trainees do not get exposure to diagnosing and managing breast diseases.

The newsletter covers all aspects of breast diseases starting from anatomy, physiology and congenital abnormalities. Nipple discharge is a common complaint with which women report to outpatient clinics. Understanding basic examination and screening tests would enable gynaecologists diagnose and treat women. Breast cancer is the most commonly occurring cancer in women, even in our country and increased rates have been observed even in younger women. Cancer screening is the most important aspect of preventing this major disease and the newsletter deals with various modalities clinicians can offer for screening. One should not forget the medicolegal issues which may crop up and all measures should be taken to prevent them.

We are sure this e - newsletter will be a ready reckoner for clinicians and they will have solutions at a click.

Happy learning and let's all prevent sufferings of women who are bothered by various breast diseases.



Dr. Suchitra N Pandit
Past President FOGSI



Dr. Parag Biniwale
Secretary ICOG

BREAST COMMITTEE OF FOGSI 2019 - 2021

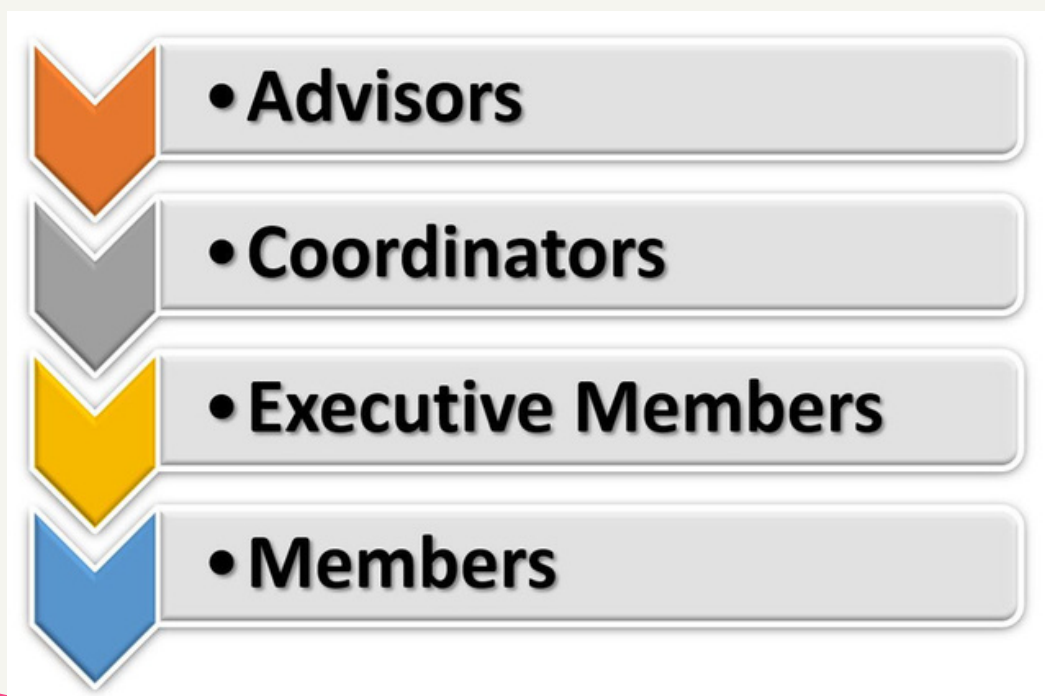Committee chairperson



Dr. Sneha S Bhuyar

**Installation at AICOG Bengaluru
9 Feb 2019**

Structure of Committee



Advisors



Dr. P. K. Shah



Dr. Suchitra Pandit



Dr. Hema Divakar




Dr. Hrishikesh Pai



Dr. Nandita Palshetkar



Dr. Mandakini Megh



Dr. M. C. Patel



**Dr. Ragini
Agrawal**



Dr. Archana Verma



Dr. Kawita Bapat



Dr. Millind Shah



Dr. Sheela Mane



Dr. M. G. Hiremath



Dr. Madhuri Patel



Dr. Bhaskar Pal



**Dr. Laxmi
Shrikhande**



Dr. Parag Biniwale



**Dr. Aswath Kumar
Raghu**



Dr. Rajat Mohanty



Dr. R. Pardesi



Dr. Arun Boruah



Dr. Sudha Prasad



Dr. Anita Singh



Dr. T. Ramani Devi



Dr. Tarini Taneja

Coordinators

National coordinator



Dr. Charulata Bapaye

East zone coordinator



Dr. Indrani Roy

West zone coordinator



Dr. Shashibala Bhonsle



Dr. Rashmi Kahar

North zone coordinator



Dr. Shashilata Kabra



Dr. Anita Rajhoria

South zone coordinator



Dr. Sasmita Dash

Executive members



Dr. Pawan Dhir



Dr. Mitra Saxena



Dr. Neharika



Dr. Shyjus



Dr. Poonam Goyal


East zone members



Dr. Prerana Keshan



Dr. Charu Modi



Dr. Samarina Kamal




Dr. Anudhriti Dutta



Dr. Madhu Sinha



Dr. Anju Turior



Dr. Monideepa Roy



Dr. Nutan Upadhyay



Dr. Priyankur Roy



Dr. Kakali Dutta



Dr. Banita Sahay



Dr. Apurba Dutta



Dr. Sandhya Panigrahi

South zone members



Dr. Vanaja




Dr. Vijay Prabha



Dr. P. A. Ramani



Dr. Manjula Appadurai



Dr. Sharda C



**Dr. Vijayalakshmi
Shesadri**



Dr. P. Mumtaz



Dr. Meghana


North zone members



Dr. Mrinalini Mani



Dr. Sushila Gupta



**Dr. Shraddha
Agrawal**



Dr. Anita Rajoriya



Dr. Sushma Sinha



Dr. Shehla Jamal



**Dr. Sarveshwari
Nautiyal**



Dr. Vineeta Mittal



Dr. Lavanya Tyagi



Dr. Kiran Shrivastav



Dr. Shivani Goel



Dr. Arati Dibya

West zone members



Dr. Mangala Wani



Dr. Pranjal Sharma



Dr. Varsha Lahade



Dr. A. Ridhorkar



Dr. Pragati Khalatkar



Dr. Dolly Mehra



Dr. Brajbala Tiwari



Dr. Alka Kuthe



Dr. Arpita Jayaswal



Dr. Jiteeka



Dr. Kirtan Vyas



Dr. Archana Dwivedi



Dr. Manisha Ghate



Dr. Nageshwari



Dr. Neerja Pauranik




Dr. Pradhan



Dr. Kanchan Madar



Dr. Kamini Patel



Dr. Neetu Keshwani




Dr. Kiran Sarda

Mass screening for Breast & Cervical at Ghatanji, Arni, Darvha, Digras Talukas of Yavatmal Feb 2019

**"AWARENESS AND MASS SCREENING
PROGRAMME"
GRAMIN RUGNALAYA, GHATANJI,
DIST. YAVATMAL**





8 March 2019 "Mahila Melawa" with Zilla Parishad, Yavatmal - 1000 Women Health Workers Felicitated



International Women's Day at Nagar Parishad, Yavatmal on 8 March 2019 - 1000 Women from Bachat Gat

“INTERNATIONAL WOMEN’S DAY” At NAGAR PARISHAD, YAVATMAL



Breast & Cervical Cancer Screening camp, Baramati With Pune Society May 2019

फॉरेन्सिकी वेट्ट कर्मिडी,
अंग्रीकलचर डेव्हलपमेंट ट्रस्ट, बरामती
न ना गंगती रती आरोग्य संघटना
रांख्या संयुक्त विद्यमाने आयोजित

रती आरोग्य व रतन आरोग्य शिबीर
रविवार, दि. १२ मे २०१९ सकाळी १०.०० ते सायं. ५.०० पर्यंत

- स्थळ -
अंग्रीकलचर डेव्हलपमेंट ट्रस्ट, दिनकर हॉल,
शारदानगर, मालेगांव कॉलनी जवळ, बरामती

Dr. Nandita Palshetkar
President
FOGSI

Dr. Sneha Bhuyar
Chairperson
FOGSI Breast Committee

Dr. Charulata Bapaye
West Zone Co-ordinator
FOGSI Breast Committee

Smt. Nandatal Pawar
Secretary
Agricultural Development Trust, Baramati

OUR ASSOCIATES

Baramati
Obstetrics & Gynaecology Society

Foundation for Research & Education
in Endoscopy (FREE), Pune

GEMS
GEMS Hospital & Endoscopy Center, Pune

Aastha
Aastha Breast Care, Pune

Agricultural
Development Trust
Baramati

Agricultural Development Trust, Baramati

Breast Camp at Baramati



Walkathon for Cancer Awareness

DR. LAXMI SHRIKHANDE, NAGPUR
NATIONAL CO-ORDINATOR

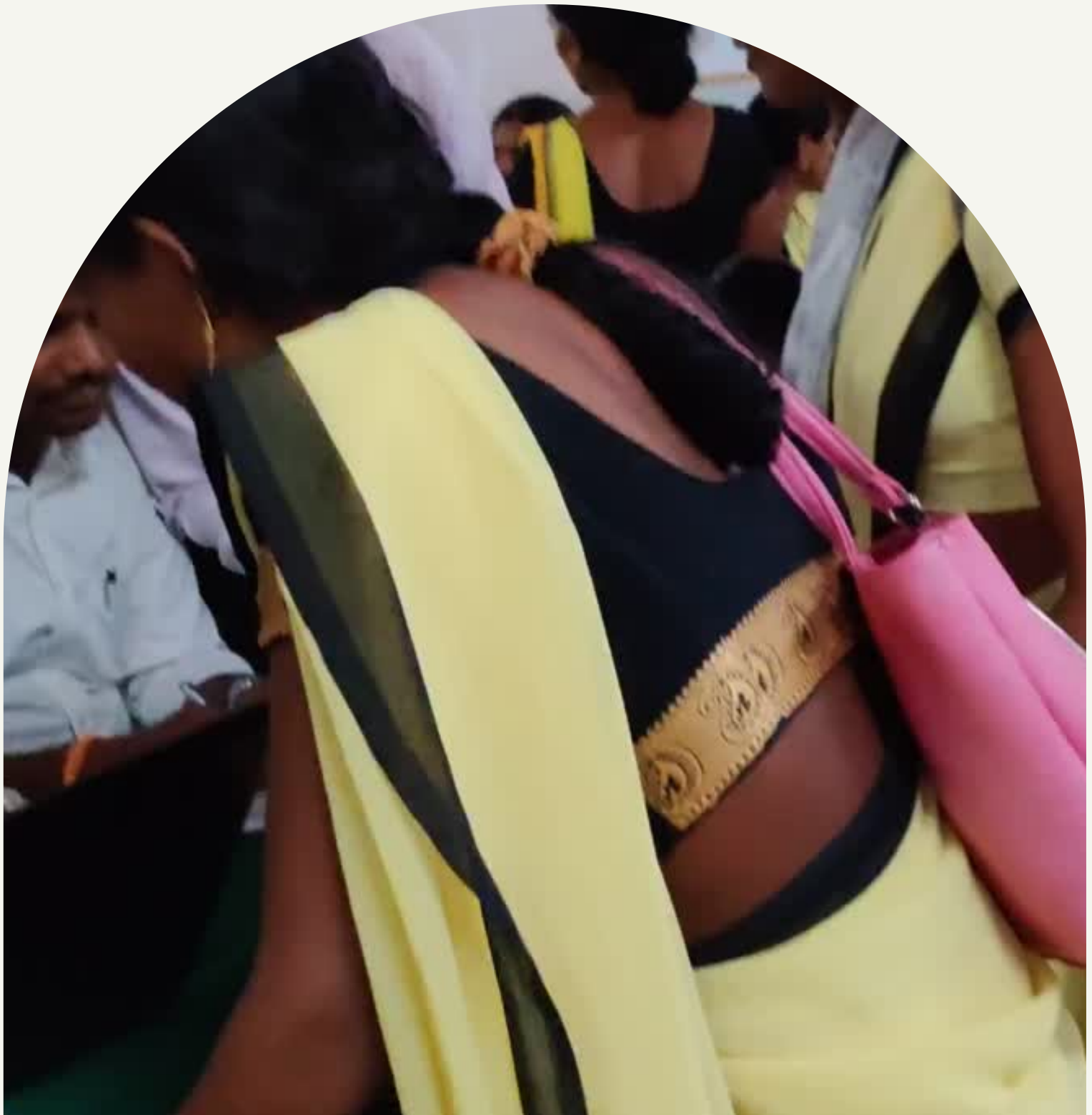

Mass Screening Program Breast & Cervical cancer for ASHA Workers with Yavatmal Ob Gy Soc October 2019 & 2500 Beneficiaries





Mass Screening Program for ASHA Workers with Yavatmal Ob Gy Society & 2500 Beneficiaries





*All the ASHA Women Workers Applauding
for Dr. Sneha S. Bhuyar*

Breast Committee Advisors



Breast Cancer Awareness with Nagpur Society- Felicitation by Central Cabinet Minister Nitinji Gadkari - 11 January 2020



एक लक्ष्य, तुम पर मेरा सौभाग्य

मंत्री गडकरी के हाथों डा. स्नेहा भुयार सम्मानित

संयुक्त तत्वावधान में नागपुर में मेमरी एनहान्समेंट अॅन्ड अॅडोलेसेंट हेल्थ कार्यक्रम का आयोजन हाल ही में किया गया था। इस आयोजन में देश के विख्यात चिकित्सक शामिल हुए थे। इस कार्यक्रम के तहत यवतमाल की प्रख्यात स्त्री रोग तथा कर्करोग विशेषज्ञ डा. स्नेहा भुयार का व्याख्यान आयोजित किया गया था। राहाटे कॉलनी परिसर के प्लॅटिनम जुबली हॉल में हुए इस कार्यक्रम के बतौर प्रमुख अतिथि केंद्रीय मंत्री नितिन गडकरी, डा. एम.के.तनेजा प्रमुख वक्ता उपस्थित थे। इस अवसर पर स्तन तथा बच्चेदानी के कैंसर विषय पर डा. स्नेहा भुयार ने उपस्थितों को मार्गदर्शन किया। मौल्यवान तथा जरूरी जानकारी के साथ दिए गए व्याख्यान और अखिल भारतीय स्तर पर स्तन तथा बच्चेदानी के कैंसर पर सरहानीय कार्य करने के लिए उन्हें नितिन गडकरी के हाथों सम्मानचिन्ह देकर सम्मानित किया गया।

» कैंसर से बचाव के लिए उल्लेखनीय कार्य करने पर मिला सम्मान

ब्यूरो | यवतमाल

संघ परिवार की ओर से पीएम मोदी के फिट इंडिया अभियान के अंतर्गत इंडियन इंस्टीट्यूट ऑफ योगा अॅन्ड नॅचुरोपॅथी के

March 2020 Women's Day Celebrations attended by more than 1500 women



FOGSI e-Conclave Webinar on Breast Cancer - Oct 2020 - 20,000 Viewers

FOGSI E CONCLAVE on Breast Cancer with Breast Committee, Oncology Committee, Public Awareness Committee

17th October 2020, Saturday Time: 3.00 pm to 6.00 pm

Theme: Jeet Jayenge Hum - Cancer Se For Community Connect
जीत जायेंगे हम - कैंसर से सामान्य जनता के लिए

 Dr Alpesh Gandhi President, FOGSI	 Dr Jaydeep tank Secretary General, FOGSI	 Dr Nandita Palshetkar Immediate Past President, FOGSI	 Dr Shaantakumari Sekhara President Elect, FOGSI	 Dr Sunil Shah Joint Secretary, FOGSI
 Dr Anita Singh Vice President, FOGSI	 Dr Abul Ganatra Vice President, FOGSI	 Dr Ragini Agarwal Vice President, FOGSI	 Dr T Ramani Devi Vice President, FOGSI	 Dr Archana Baser Vice President, FOGSI
 Dr Sneha Bhoyar Chairperson, Breast Committee, FOGSI	 Dr Kalyan Baramade Chairperson, PAC, FOGSI	 Dr Bhagyashree Nayak Chairperson, Oncology Committee, FOGSI	 Dr Madhuri Patel Dr. Secretary Genet., FOGSI	 Dr Savana Khadilkar Treasurer, FOGSI
 Dr Parikshit Tank Joint Treasurer, FOGSI	MOC			
 Dr Nehalika Malhotra Chairperson, YTP Committee, FOGSI	 Dr Chitra Bapaye National coordinator, Breast committee, FOGSI			
Chief Guest		Guest of honour		
 Dr C S Pramesh Director, Tata Memorial Hospital, Mumbai	 Dr Anil Tibrewala Consultant Surgeon, Mumbai	 Dr Ashok Mehta President, Medical Ring BK	 Dr Suchitra Pandit President, FOGSI, 2014	 Rita, Jyoti Bahadri President, FOGSI Fellowship Council

FOGSI E CONCLAVE on Breast Cancer with Breast Committee, Oncology Committee, Public Awareness Committee

17th October 2020, Saturday Time: 3.00 pm to 6.00 pm

Theme: Jeet Jayenge Hum - Cancer Se For Community Connect
जीत जायेंगे हम - कैंसर से सामान्य जनता के लिए

Speaker Dr Anil Tibrewala Chairperson: Dr Suchitra Pandit Topic: Post Cancer Cosmetic Breast Surgery	Speaker Dr Sneha Bhoyar Chairperson: Dr Mona Shah Topic: Epidemiology of Breast Cancer in India
Speaker Dr Ragini Agarwal Chairperson: Dr Anita Singh Topic: Self Breast Examination	Speaker Dr Sneha Bhoyar Chairperson: Dr Anjana Chauhan Topic: Clinical Breast Examination
Speaker Dr Sneha Bhoyar Chairperson: Dr Parag Binwale Topic: Confirm or Rule out Breast Cancer with Investigations	Speaker Dr Sneha Bhoyar Chairperson: Dr Seetha Bhaskar Pai Topic: Treatment Options

Panel Discussion Breast Cancer survivors & Experience Sharing

Moderators

 Dr Sneha Bhoyar Chairperson, Breast Committee, FOGSI	 Dr Bhagyashree Nayak Chairperson, Oncology Committee, FOGSI
---	--

Panelists

Dr Mitras Saxena	Dr Shashibala Bhosle	Dr Ragini Singh
Dr Nupur Gupta	Dr Meetu Narang	Dr Rohini Patil

Role of Exercise in Prevention of Breast cancer

Prize Declaration

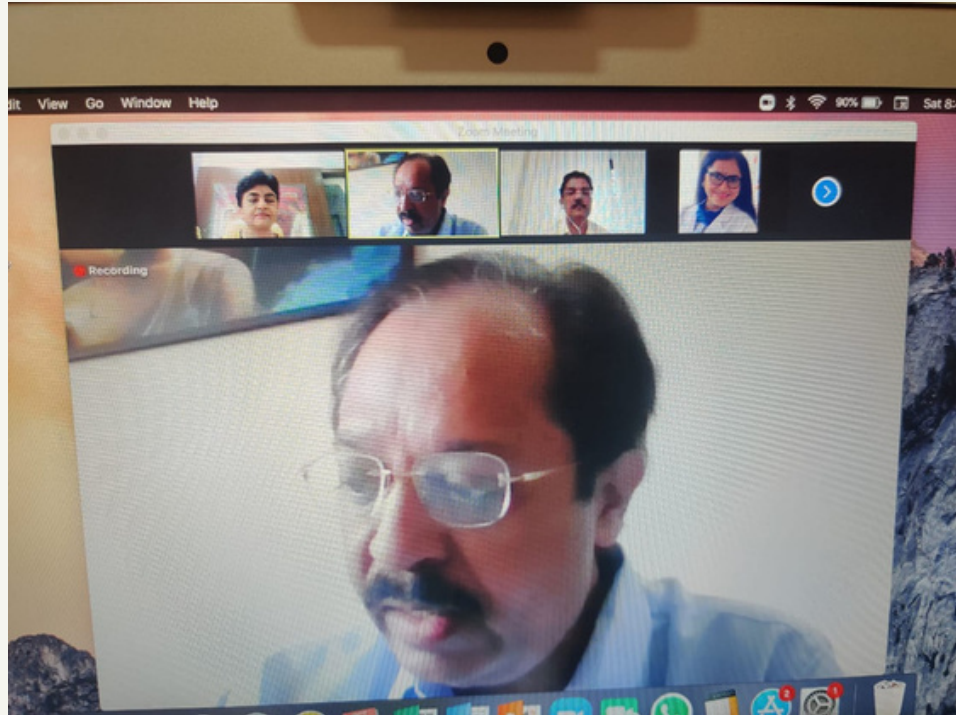
 Dr Alpesh Gandhi President, FOGSI	 Dr M C Patel Ex VP, FOGSI	 Dr M G Bharambh Ex VP, FOGSI	 Dr Sneha Bhoyar Breast Surgeon, Pune
--	----------------------------------	-------------------------------------	---

Judges

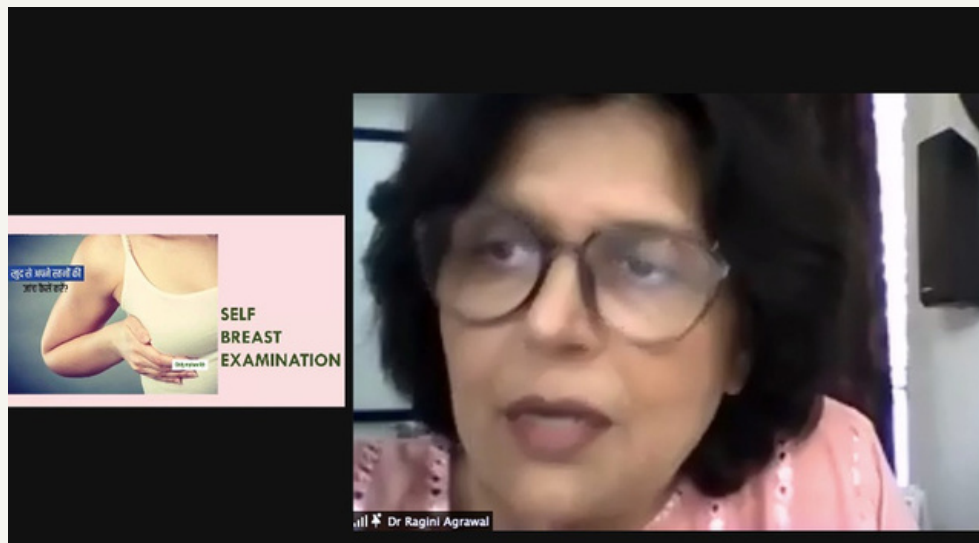
Scientific exercises (10 min) - Dr Shubhdha Neel

Link to Join:
<https://www.facebook.com/FOGSI2020>
<https://www.youtube.com/c/FOGSI2020/live>

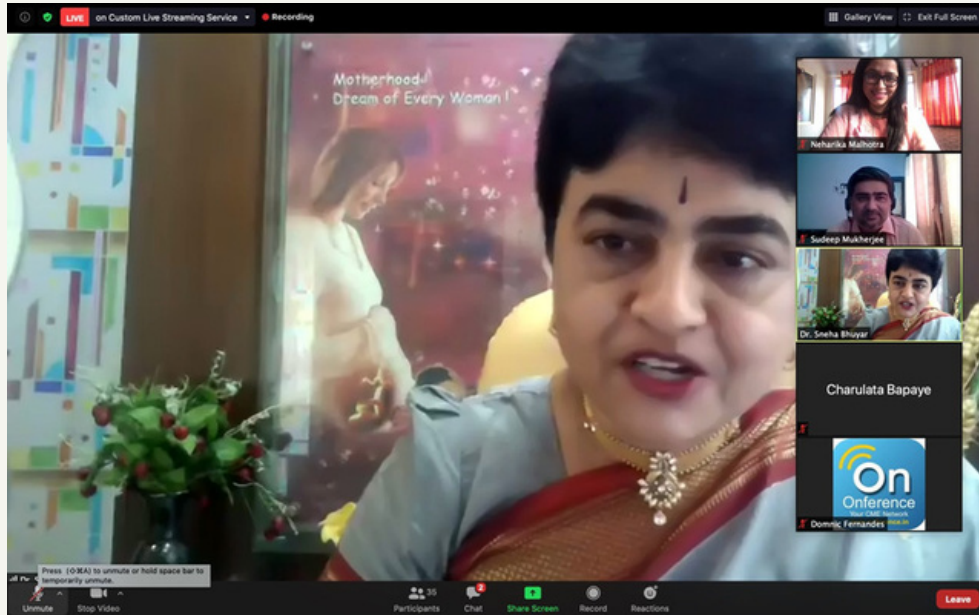
FOGSI e - Conclave Webinar



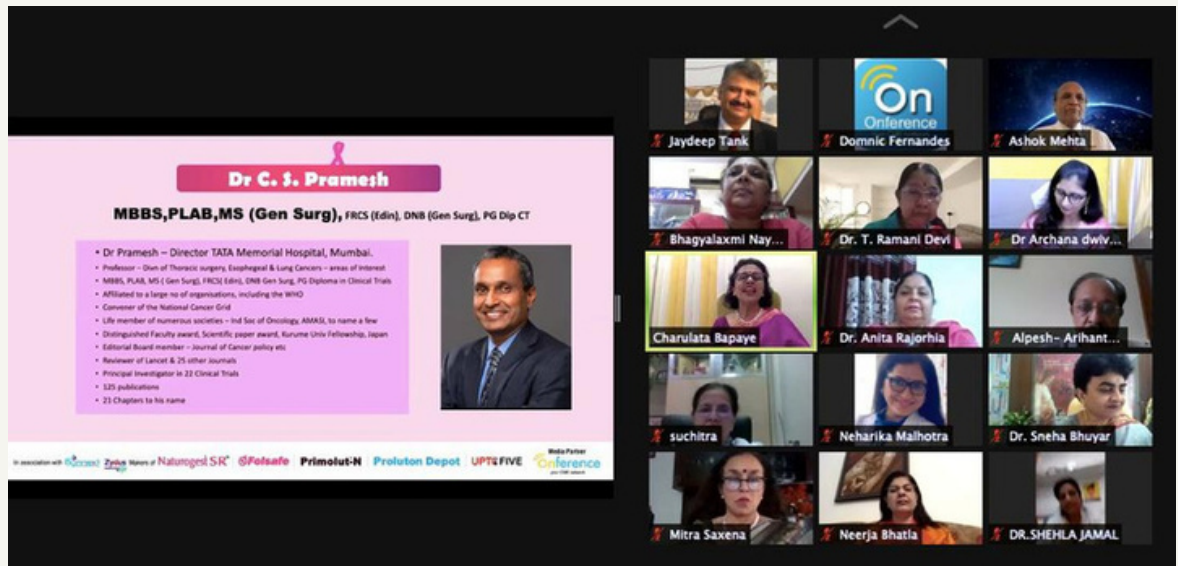
FOGSI e - Conclave Webinar



FOGSI e - Conclave Webinar



FOGSI e - Conclave Webinar




CONTENTS



ANATOMY OF BREAST

Dr. P. K. Shah

1



PHYSIOLOGICAL CHANGES IN BREAST ACCORDING TO AGE AND MENSTRUAL CYCLE

- Dr. Gurpreet Kaur Sandhu
- Dr. Rajendrasing Pardeshi

6



CONGENITAL ANOMALIES OF THE BREAST

- Dr. T. Ramani Devi
- Dr. S. Prasanna Kumar

10



BENIGN BREAST DISEASES

- Dr. Sheela V Mane
- Dr. Amrita Prabhu
- Dr. Tara R

15



ABNORMAL NIPPLE DISCHARGE

- Dr. Neeta .A.Keshwani
- Dr. Sneha .S.Bhuyar

19



SCREENING FOR BREAST CANCER

- Dr. Mrinalini Mani
- Dr. Shashilata Kabra Maheshwari

23




CONTENTS



BREAST CANCER AND ITS MANAGEMENT

- Dr. Charulata Bapaye
- Dr. Kawita Bapat

28



LEGAL ISSUES IN BREAST DISEASES

- Dr. M.C. Patel

33

ANATOMY OF BREAST



Dr. P. K. Shah

Past President FOGSI

Ex Prof. Dept of ObGyn. Seth G. S. Medical College,
KEM Hospital, Mumbai

INTRODUCTION

- The breast is the most superficial structure in the anterior thoracic wall, especially in females where it is well developed. The mammary glands are modified sweat glands in the subcutaneous tissue overlying the pectoral muscles with the amount of fat surrounding the glandular tissue determining the size of the breast. The greatest prominence of the breast is the nipple surrounded by a circular pigmented area of skin called areola.
- The mammary gland in breast is usually accessory to reproduction in females and are rudimentary and almost functionless in men, consisting of only few ducts.

GROSS ANATOMY

- The roughly circular base of the female breast extends transversely from the lateral border of the sternum to the mid-axillary line where it covers the 2nd to the 6th ribs. The nipple is situated on the 4th intercostal space about 10cm from the median plane. A small part of the mammary gland may extend along the infero-lateral aspect of the Pectoralis Major muscle towards the axilla to form the axillary tail of Spence. A layer of loose connective tissue (the retromammary space) separates the breast from the deep fascia and provides some degree of movement over underlying structures. The mammary gland is firmly attached to the dermis of the overlying skin by skin ligaments the suspensory ligaments (of Cooper) of the breast.
- During puberty, the breasts normally grow because of glandular development and increased fat deposition. The areolae and nipples also enlarge.

- Breast size and shape result from genetic, racial, and dietary factors. The lactiferous ducts give rise to buds that form 15 to 20 lobules of glandular tissue, which constitute the gland. Each lobule of the breast is drained by a lactiferous duct that usually opens independently on the nipple. The system of ducts in the breast is configured like an inverted tree, with the largest ducts just under the nipple and successively smaller ducts in the periphery. After several branching generations, small ducts at the periphery enter the breast lobule, which is the milk-forming glandular unit of the breast. Deep to the areola, each duct has a dilated portion, the lactiferous sinus, in which a small droplet of milk accumulates or remains in the nursing mother.

AREOLA

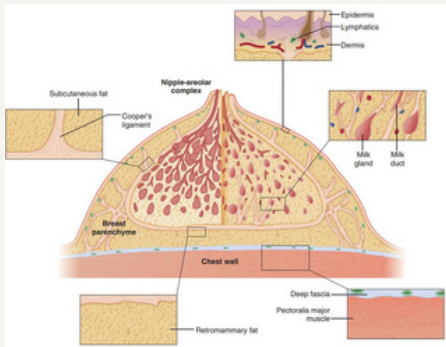
- It contains numerous sebaceous glands that get enlarged during pregnancy. It secretes an oily substance which gives a protective lubricant to the areola itself and the nipple. It is particularly subject to chafing and irritation as mother and baby begins the nursing experience.

NIPPLE

- These are conical or cylindrical prominence in the centre of the areola with no fat, hair or sweat gland. In a nulliparous woman, it is usually at the level of the 4th intercostal space, however, the position of the nipple varies.
- It is composed mainly of circularly arranged smooth muscle fibre that compresses the lactiferous gland

during lactation and erects the nipple in response to stimulation. i.e. when a baby begins to suckle or from a touch.

• **Fig 1: Cut-away diagram of a mature resting breast.**



MICROSCOPIC ANATOMY

- The mature breast is composed of three principal tissue types:
 - (1) Glandular epithelium
 - (2) Fibrous stroma and supporting structures
 - (3) Adipose tissue. The breast also contains lymphocytes and macrophages.

• In adolescents, the predominant tissues are epithelium and stroma. In postmenopausal women, the glandular structures involute and are largely replaced by adipose tissue.

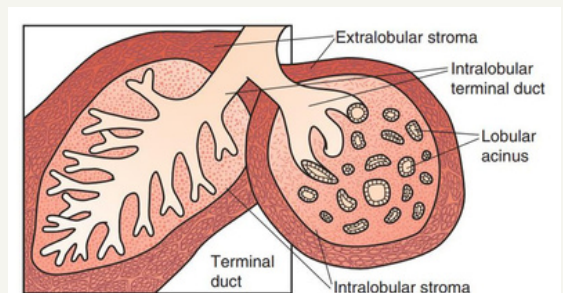
• Cooper's ligaments provide shape and structure to the breast as they course from the overlying skin to the underlying deep fascia. Because these ligaments are anchored into the skin, infiltration of these ligaments by carcinoma commonly produces tethering, which can cause dimpling or subtle deformities on the otherwise smooth surface of the breast.

• The glandular apparatus of the breast is composed of a branching system of ducts, organized in a radial pattern spreading outward and downward from the nipple-areolar complex. It is possible to cannulate individual ducts and visualize the lactiferous ducts with contrast agents. Each major duct has a dilated portion (lactiferous sinus) below the nipple-areolar complex. These ducts converge through a constricted orifice into the ampulla of the nipple. Each of the major ducts has progressive generations of branching and ultimately ends in the terminal ductules or acini. The acini are the milk-forming glands of the lactating breast and, together

with their small efferent ducts or ductules, are known as lobular units or lobules.

- As shown in Figure 2, the terminal ductules are invested in a specialized loose connective tissue that contains capillaries, lymphocytes, and other migratory mononuclear cells. This intralobular stroma is clearly distinguished from the denser and less cellular interlobular stroma and from the adipose tissue within the breast. The entire ductal system is lined by epithelial cells, which are surrounded by specialized myoepithelial cells that have contractile properties and serve to propel milk formed in the lobules toward the nipple. Outside the epithelial and myoepithelial layers, the ducts of the breast are surrounded by a continuous basement membrane containing laminin, type IV collagen, and proteoglycans. The basement membrane layer is an important boundary in differentiating in situ from invasive breast cancer. Continuity of this layer is maintained in ductal carcinoma in situ (DCIS), also termed noninvasive breast cancer. Invasive breast cancer is defined by penetration of the basement membrane by malignant cells invading the stroma.

• **Fig 2: Mature resting lobular unit**



ARTERIAL SUPPLY

- The blood supply to the breast is derived from the following branches of blood vessels, Lateral thoracic and thoracoacromial arteries which are branches of the second part of the axillary artery. Posterior intercostal arteries a branch of the thoracic aorta in the 2nd, 3rd and 4th intercostal spaces. Medial mammary branch of perforating branches & anterior intercostal branches of the internal thoracic artery.

VENOUS SUPPLY

- Venous drainage of the breast is mainly by the axillary vein with some assistance from the internal thoracic vein.

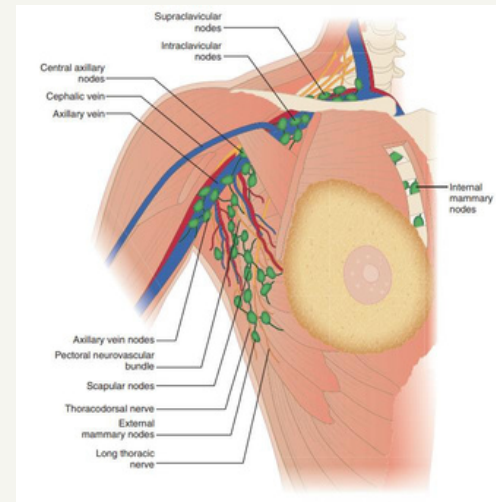
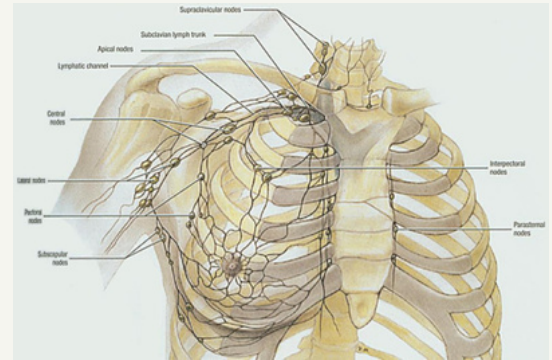
LYMPHATIC DRAINAGE

- Lymphatic drainage of the breast is extremely important as cancer of the breast is very common. Since cancer cells metastasize via lymphatics, the enlargement of the lymph nodes that drains the breast gives information about the spread of cancer.
- The axillary lymph nodes, grouped as shown in Figure 3, are found within the loose areolar fat of the axilla; the number of lymph nodes varies according to the size of the patient. The axillary nodes are typically described as three anatomic levels defined by their relationship to the pectoralis minor muscle.
- Level I nodes are located lateral to the lateral border of the pectoralis minor muscle.
- Level II nodes are located posterior to the pectoralis minor muscle.
- Level III nodes are located medial to the pectoralis minor muscle and include the subclavicular nodes. Level III nodes are easier to visualize and remove when the pectoralis minor muscle is divided.
- Drainage generally proceeds in a stepwise fashion from level I to level II, to level III, and finally into the thorax. Lymph nodes in the space between the pectoralis major and minor muscles are termed the interpectoral group or Rotter's nodes, as described by Grossman and Rotter.
- Lymph flows from the skin to the subareolar plexus and then into the interlobular lymphatics of the breast parenchyma. Appreciation of lymphatic flow is important for performing successful sentinel lymph node surgery. The superficial lymphatics from skin over the breast except the nipple and areola drain radially into the axillary, supraclavicular and internal mammary group of lymph nodes. The deep lymphatics from the nipple, areola and parenchyma drains as follows; 75% of lymph especially from the lateral quadrant of the breast drains mostly into anterior, some into posterior and apical group of axillary lymph nodes. These also communicate with the lateral and central groups as well. Most of the remaining 25% lymph, particularly from the medial quadrants drain to the parasternal nodes or to the opposite breast while lymph from the lower

quadrants drain to the inferior phrenic (abdominal) nodes. Lymph from the axillary nodes drains into the infraclavicular and supraclavicular nodes.

- 2,3 Unless these nodes are specifically exposed, they are not encompassed in surgical procedures that preserve the pectoral muscles. Lymphatic channels are abundant in the breast parenchyma and dermis. Specialized lymphatic channels collect under the nipple and areola and form Sappey's plexus.

• Fig 3 : Lymphatic drainage of the breast.



• Fig 4: Contents of the axilla

- In this diagram, there are five named and contiguous groupings of lymph nodes in the full axilla. Complete axillary dissection, as done in the historical radical mastectomy, removes all these nodes. However, the subclavicular nodes in the axilla are continuous with the supraclavicular nodes in the neck and nodes between the pectoralis major and minor muscles, called the interpectoral nodes in this diagram (also known as Rotter's lymph nodes). The **sentinel lymph node** is functionally the first node in the axillary chain and anatomically is usually found in the external mammary group. The relative positions of the long thoracic, thoracodorsal, and medial pectoral nerves are shown. These major nerves along with the pectoral neurovascular bundle should be preserved during surgery.

NERVE SUPPLY OF THE BREAST

- Nerve supply to the breast is derived from the Anterior and Lateral Cutaneous branches of the 4th-6th intercostal nerves. The branches of the intercostal nerve passes through the deep fascia covering the pectoralis major muscle to reach the skin, including the breast in the subcutaneous tissue overlying this muscle. Coursing close to the chest wall on the medial side of the axilla is the long thoracic nerve, also known as the external respiratory nerve of Bell, which innervates the serratus anterior muscle. This muscle is important for fixing the scapula to the chest wall during adduction of the shoulder and extension of the arm, and division of the nerve may result in the winged scapula deformity. For this reason, the long thoracic nerve is preserved during axillary surgery. The second major nerve encountered during axillary dissection is the thoracodorsal nerve, which innervates the latissimus dorsi muscle. The thoracodorsal nerve and vessels are preserved during dissection of the axillary lymph nodes. The medial pectoral nerve innervates the pectoralis major muscle and lies within a neurovascular bundle that wraps around the lateral border of the pectoralis minor muscle. This bundle should be preserved during standard axillary dissection. **[Fig 4]** The large sensory intercostal brachial or brachial cutaneous nerves span the axillary space and supply sensation to the under surface of the upper part of the arm and skin of the chest wall along the posterior margin of the axilla. Dividing these nerves results in cutaneous anesthesia in these areas, and the possibility of this outcome should be explained to patients before axillary dissection.

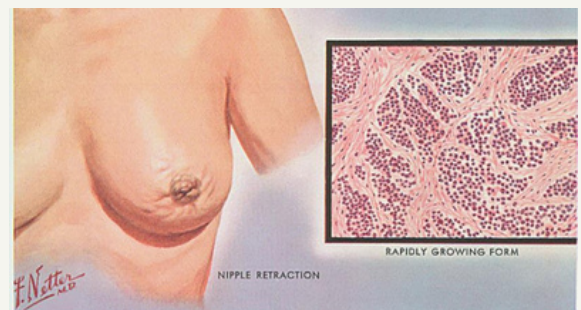
APPLIED ANATOMY

- Polymastia, Polythelia and Amastia: These clinical conditions are interrelated. Polymastia; this is a condition when there is an extra number of breasts. Polythelia; means exceeding the normal number of nipples. Polymastia may occur superior or inferior to the normal breast and could occasionally develop in the axilla or anterior abdominal wall. The extra breast may consist of only rudimentary nipple and areola, which may be mistaken for a mole (nevus) until they change pigmentation with the normal nipple during pregnancy. Polymastia may occur anywhere along the line extending from the axilla to the groin as this is the location where the embryonic mammary ridge develops from. In either sex, there

may be no breast or there could be a nipple and no glandular tissue a condition known as Amastia.

- Gynaecomastia is a situation of the enlargement of the male breast which commonly occur in puberty but could accompany aging and drug related e.g. after treatment of prostate cancer with Diethylstilbestrol. It could also occur by a sudden change in the metabolism of sex hormones by the liver. Approximately 40% of post-pubertal males with Klinefelter's syndrome (xxy trisomy) exhibits gynaecomastia.
- Breast quadrants: For the anatomical location and description of tumors, the surface of the breast is divided into 4 quadrants, upper outer, lower outer, upper inner and lower inner. Incisions: Incisions into the breast are usually made radially to avoid cutting the lactiferous ducts.
- Advanced Breast tumour: Tumors may grow through retromammary space and subsequently invade deep fascia & pect. major muscle which leads to fixation of malignant breast lesion to chest wall, shortens suspensory (Cooper's) ligaments and leads to irregular dimpling of skin or retraction of nipple.

• Fig 5 : Advanced Breast carcinoma



REFERENCES

1. Moore KL. The upper limb. In: Clinically oriented anatomy. 2nd ed. Baltimore, Md: Williams & Wilkins, 1985; 660.
2. Cody HS, Egeli RA, Urban JA. Rotter's node metastases. Therapeutic and prognostic considerations in early breast carcinoma. (1984) Annals of surgery. 199 (3): 266-70.
3. Tor Wo Chiu. Stone's Plastic Surgery Facts: A Revision Guide, Fourth Edition. (2018) ISBN: 9781351734806

- 4. Arvy L, Rivet R. [Marie Philibert Constant Sappey (1810-1896). The man and the lymphologist]. (1976) Bulletin de l'Association des anatomistes. 60 (168): 63-79.

PHYSIOLOGICAL CHANGES IN BREAST ACCORDING TO AGE AND MENSTRUAL CYCLE



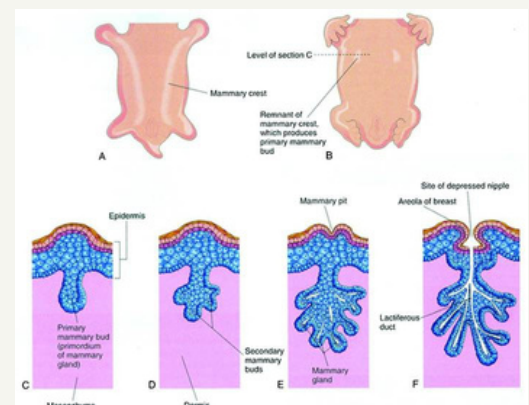
Dr. Gurpreet Kaur Sandhu,(MBBS,DGO),
CSMSS Mahavidyalaya
Aurangabad (MS).



Dr. Rajendrasing Pardeshi, MBBS,DGO,FICOG),
Jijai Maternity & Nursing home,
Garkheda, Aurangabad (MS).

- Mammalia are so named based on the presence of the mammary gland in the breast. The mammary gland is an epidermal appendage, derived from the apocrine glands. The human breast consists of the parenchyma and stroma, originating from ectodermal and mesodermal elements, respectively. Development of the human breast is distinctive for several reasons. The human breast houses the mammary gland that produces and delivers milk through development of an extensive tree-like network of branched ducts. It is also characterized by cellular plasticity, with extensive remodelling in adulthood, a factor that increases its susceptibility to carcinogenesis. Also, breast development occurs in distinct stages via complex epithelial-mesenchymal interactions, orchestrated by signalling pathways under the regulation of systemic hormones. Congenital and acquired disorders of the breast often have a basis in development, making its study essential to understanding breast pathology.

- As early as 4 to 6 weeks of gestation, mammary-specific progenitor cells may be seen. Around day 35 of gestation, proliferation of paired areas of epithelial cells in the epidermis of the thoracic region occurs. These discrete areas of proliferation extend in a line between the fetal axilla and inguinal region and form two ridges called the mammary crests or milk lines



PRENATAL DEVELOPMENT

- Prenatal breast development can be classified into two main processes; formation of a primary mammary bud and development of a rudimentary mammary gland. The earliest stages of embryogenesis are largely hormone independent; hormones and regulatory factors are important for development in the second trimester.

- Development of the mammary gland.
- **(A)** Ventral view of an embryo at 28-days gestation showing mammary crests.
- **(B)** Similar view at 6-week gestation showing the remains of the mammary crests.
- **(C)** Transverse section of a mammary crest at the site of the developing mammary gland.
- **(D-F)** Similar sections showing successive stages of breast development between the 12th week of gestation and birth.
- Toward the end of the first trimester the primary mammary buds begin to grow downwards into the underlying mesenchyme, under an inductive

FIRST TRIMESTER

influence of regulatory factors secreted by the mesenchyme. Next, the primary mammary bud enlarges and moves from a more dorsal to ventral position. Indentations along its basolateral margin appear, becoming sites for the future secondary mammary outgrowths. This core of cells continues to evaginate into the underlying stroma and becomes surrounded by a more cellular zone of fibroblast like cells within a collagenous mesenchyme.

- At the end of the first trimester of pregnancy, a well-defined mammary bud penetrating into the upper dermis can be observed. Two distinct populations of epithelial cells (central and basal) can be identified. Concomitantly, the mesenchymal cells differentiate to form fibroblasts, smooth muscle cells, capillary endothelial cells, and adipocytes.

SECOND TRIMESTER

- Secondary epithelial buds appear from the indentations on the main mammary bud. Each secondary epithelial bud grows vertically into the mesenchyme surrounding the primary bud and has a slender stalk and bulbous end. The secondary epithelial sprouts canalize and coalesce forming secondary buds that give rise to lactiferous ducts. The epithelial cells lining the lactiferous ducts are arranged in two layers, with the layer adjacent to the lumen gaining secretory function while the basal layer differentiates into myoepithelial cells.
- By 6 months of gestational age, the basic framework of the gland is established. A well-defined tubular architecture in a bed of dense fibroconnective tissue stroma is noted at this stage. This is around the time breast tissue in both boys and girls can be apparent.

THIRD TRIMESTER

- During the final weeks of gestation, the loose fibroconnective tissue stroma increases in vascularity. Due to a complex interplay between fetal, placental, and maternal hormones that has not yet been elucidated, limited secretory activity in the late-term fetus and newborn infant may occur. The failure of preterm infants to develop breast nodules or secrete milk after birth indicates that the intrauterine environment is essential for breast development. Preterm infants do not develop breast nodules or secrete milk after birth, further lending

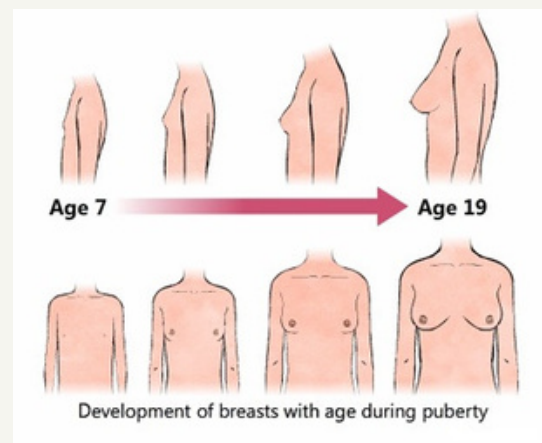
evidence to the fact that the intrauterine environment is essential for breast development.

- At term, approximately 15 to 20 lobes of glandular tissue have formed, each containing a lactiferous duct that opens onto the breast surface through the mammary pit. Both the surrounding skin and the fibrous suspensory ligaments of Cooper that anchor the breast to the pectoralis major fascia provide support to the breast.

PUBERTAL FEMALE BREAST DEVELOPMENT

GROSS ANATOMIC CHANGES

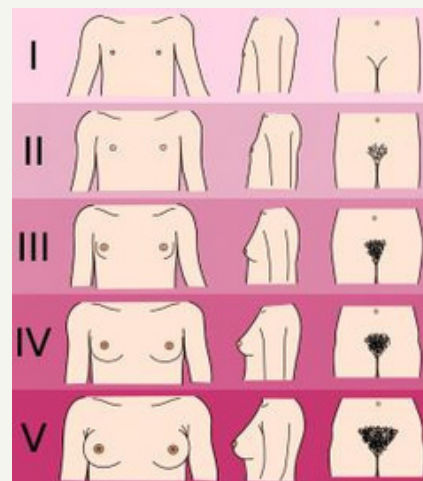
- Between the ages of 8–13 years, girls start developing breasts. Morphologically (that is in terms of form and shape), breasts look like a cone with the base at the chest wall and the apex at the nipple. It is possible that one of the breasts grows faster than the other but by the time the breasts are fully developed the differences in their shape and size are reduced. For a majority of girls there is a small difference in shape and size of the two breasts which is permanent and is totally normal. The size of the breasts and the time when it starts to grow also varies on an individual basis.



- Tanner described the most well-accepted macroscopic stages of development in the breast at puberty. These gross anatomic changes begin with stage 1, the preadolescent phase with only elevation of the papilla. At this point, there is no additional development of the stroma or parenchyma beyond what has occurred in infancy. Breast development is generally the first secondary sexual characteristic to develop, preceding pubic hair development by about 6 months. Although the pubertal surge of estrogen is the immediate stimulus to mammary

development, the action of estrogen depends upon the presence of pituitary growth hormone and the ability of growth hormone to stimulate production of insulin-like growth factor-1 (IGF-1) in the mammary gland. The age range in which this can occur is 8½ to 13½ years. No breast development by 14 years of age in girls should prompt further investigation.

- **Tanner stage 2** involves formation of the breast bud with elevation of the nipple as well as a small mound of breast tissue along with enlargement of the diameter of the areola. The average age of girls at this stage is 11 years in a British cohort and has been shown to occur 6 months earlier in the United States. There is recent literature pointing toward an earlier age at onset of breast development in girls in the United States (average age 9.8 vs. 10.8 years over approximately a decade). The normal range of thelarche is from 8½ to 13 years.
- Clinically, Tanner stage 2 of breast development correlates with the entity of thelarche. **Tanner stage 3**, attained at an average age of 12.5 years, is characterized by further enlargement of the breast and areola. No separation of the contours is noted at this time. Between Tanner stages 2 and 3, discrepancy in size between the breasts of a pubertal girl is commonly seen and tends to become less noticeable by **Tanner stage 4** and 5. If marked breast asymmetry is persistent, reconstructive surgery may be a consideration, generally when **Tanner 5** breast maturity is reached. Marked discrepancy between breast size in puberty, particularly if persistent, is presumed to be due to poor mammary bud development in the smaller breast.
- During Tanner stage 4, at the average age of 13 to 14 years, there is enlargement of the nipple and areola, leading to the formation of a secondary mound on the breast. Menarche tends to occur between Tanner stage 3 and Tanner stage 4. Some girls may progress from Tanner stage 3 to 5 without a transitory stage 4.
- Tanner stage 5 is characterized by the recession of the areola on to the breast with resulting loss of the separation of contours. This stage is attained by an average age of 15 years.



• Tanner Staging of Female

WHAT CYCLICAL CHANGES HAPPEN TO THE BREASTS DURING THE MENSTRUAL CYCLE?

- Each month, women go through changes in the hormones that make up the normal menstrual cycle. The hormone estrogen is produced by the ovaries in the first half of the menstrual cycle. It stimulates the growth of milk ducts in the breasts. The increasing level of estrogen leads to ovulation halfway through the cycle. Next, the hormone progesterone takes over in the second half of the cycle. It stimulates the formation of the milk glands. These hormones are believed to be responsible for the cyclical changes that many women feel in their breasts just before menstruation. These include swelling, pain, and soreness.
- During menstruation, many women also have changes in breast texture. Their breasts may feel very lumpy. This is because the glands in the breast are enlarging to get ready for a possible pregnancy. If pregnancy does not happen, the breasts go back to normal size. Once menstruation starts, the cycle begins again.

WHAT HAPPENS TO THE BREASTS AT MENOPAUSE?

- By the time a woman reaches her late 40s and early 50s, perimenopause is starting or is well underway. At this time, the levels of estrogen and progesterone begin to change. Estrogen levels dramatically decrease. This leads to many of the symptoms commonly linked to menopause. Without estrogen, the breast's connective tissue becomes dehydrated and is no longer elastic. The breast tissue, which was prepared to make milk, shrinks and loses shape. This leads to the "saggy" breasts associated with women of this age.

- Women who are taking hormone therapy may have some of the premenstrual breast symptoms that they had while they were still menstruating, such as soreness and swelling. But if a woman's breasts were saggy before menopause, this will not change with hormone therapy.

REFERENCES

- (1) <https://teachmephysiology.com/>
- (2) <https://www.hopkinsmedicine.org/>
- (3) <https://Sciencedirect.com>
- (4) Clinically Oriented Embryology. 9th ed. 2013, Elsevier.

CONGENITAL ANOMALIES OF THE BREAST



Dr. T. Ramani Devi, MD; DGO; FICS; FICOG;

National Vice President FOGSI 2020
Consultant Obstetrician and Gynecologist
Director Ramakrishna Medical Centre LLP
Director Janani Fertility Centre
Trichy.

Dr. S. Prasanna Kumar, MS., FIAGES., FAGIE.,

Consultant Surgeon
Ramakrishna Medical Centre LLP
Trichy.



EMBRYOLOGY

• 6th week of gestation

- During sixth week of gestation, paired ectodermal thickenings termed mammary ridges or milk lines develop on the ventral surface of the embryo and extend towards the midline from the axillae to the medial thigh. In normal human development, these ridges disappear except at the level of the fourth intercostal space on the anterior thorax, where the mammary gland subsequently develops.

• 7th week of gestation

- The remnant of the mammary ridge ectoderm begins to proliferate and is termed the primary mammary bud. This primary bud subsequently begins to grow downwards as a solid diverticulum into the underlying dermis during the seventh week.

• 10th week of gestation

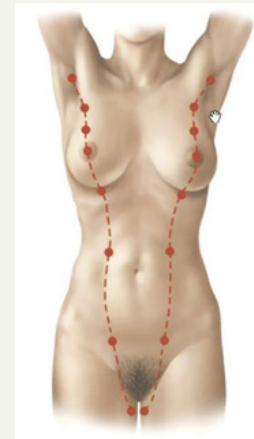
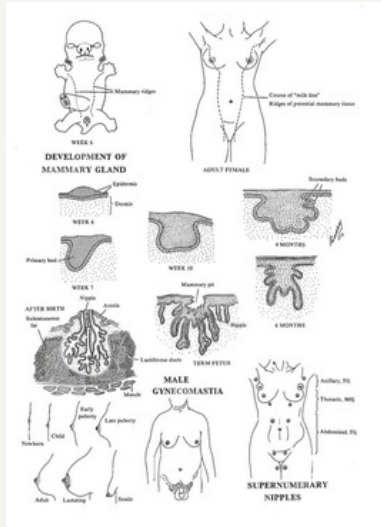
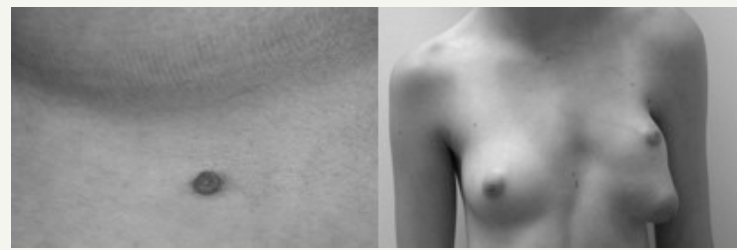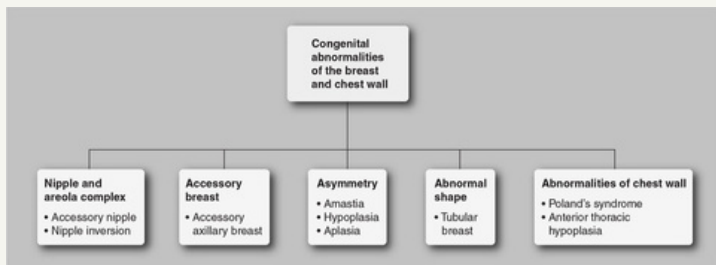
- The primary bud begins to branch, yielding secondary buds by the 12th week, which eventually develop into the mammary lobules of the adult breast. This initial down growth and subsequent branching has been shown to occur as the result of an inductive influence of the extracellular matrix of the mesoderm on the primary mammary bud. The adipose tissue in the underlying mesoderm represents a significant store of lipids for the production of hormones and growth factors, which are then available to promote and regulate the growth of the developing mammary gland.

• 20th week of gestation

- During the remainder of gestation, these buds continue lengthening and branching. During the 20th week, small lumina develop within the buds that coalesce and elongate to form the lactiferous ducts. The canalization of the mammary buds with formation of the lactiferous ducts is induced by placental hormones-(progesterone, growth hormone, insulin like growth factor, estrogen, prolactin, adrenal corticoids, and triiodothyronine) entering the fetal circulation.

• Term gestation

- At term, approximately 15-20 lobes of glandular tissue have formed, each containing a lactiferous duct. Support for the breast comes from both the skin envelope and the fibrous suspensory ligaments of Astley Cooper that anchor the breast to the pectoralis major fascia.
- The lactiferous ducts drain into retro-areolar ampullae that converge into a depressed pit in the overlying skin. Each of the 15-20 lobes of the mammary gland has an ampulla with an orifice opening into this mammary pit. Stimulated by the inward growth of the ectoderm, the mesoderm surrounding this area proliferates, creating the nipple with circular and longitudinally oriented smooth muscle fibers. The surrounding areola is formed by the ectoderm during the fifth month of gestation. The areola also contains other epidermal glands, including glands of Montgomery which are sebaceous glands that serve to lubricate the areola.

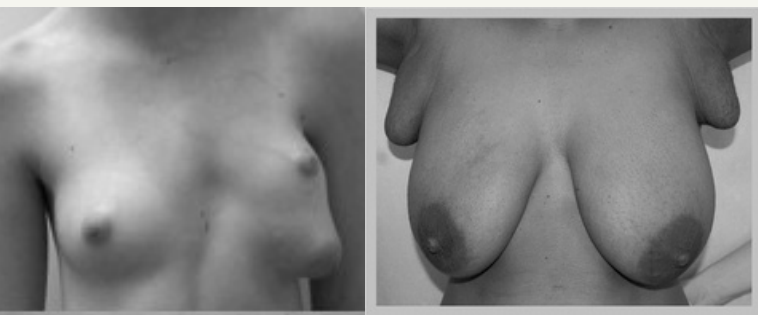

POLYTHELIA (MULTIPLE NIPPLES)

- Polythelia is the presence of supernumerary nipples (SNNs).
- It is important for Paediatricians to note for this in the newborn due to the preponderance for growth and change with increasing hormone levels.
- Most SNNs develop along the embryonic milk line, axillary, thoracic and abdominal being 5%, 90% and 5% respectively.
- However, they may also appear on the back, shoulder, thigh, face, or vulva.
- The SNN can develop similar pathologies as a normal breast, including breast neoplasia.
- Although there is little evidence to support association of SNNs with other congenital anomalies or syndromes, they are often familial.
- There is no correlation with gender. There is no predilection for the right or left side; however, there is a lower incidence of bilateral SNNs.
- The management of SNNs has traditionally been observation. Changes to the pigmented lesion should be treated as for any melanocytic nevus, with early excision and histopathological assessment. An oncologist should evaluate nipple growth that occurs at a time other than childhood, puberty, or pregnancy.

POLYMASTIA

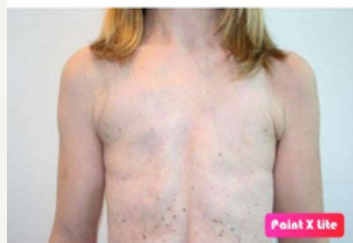- Polymastia has an even lower incidence than polythelia and also occurs along the embryonic milk line. Like polythelia, it is usually sporadic, but can have familial inheritance.
- Unlike polythelia, polymastia can be associated with other congenital anomalies, particularly thoracic and renal.
- **Treatment**
 - Treatment is variable and depends on the size and location of the supernumerary breast gland and nipple. Simple mastectomy is the option in patients who present with a third distinct breast mound. Disruption of the inframammary fold and soft tissue envelope of the remaining breast should be prevented when possible.
 - In cases where the accessory breast is adjacent to the native breast, tissue-sparing techniques with skin de-epithelialization and accessory nipple excision can usually restore the mound to a normal appearance and location.
 - Corrective surgery for polymastia should be performed when breast development is complete and final breast tissue volumes have been achieved. It is often difficult to predict the form and position of the accessory breast mound, nipple and early excision may ultimately compromise the eventual outcome.



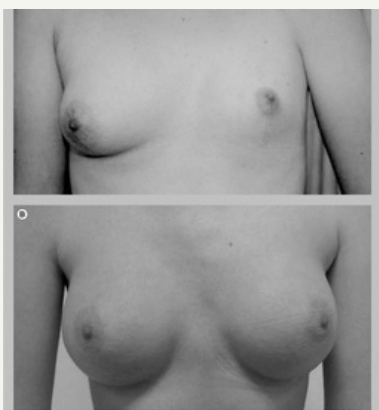
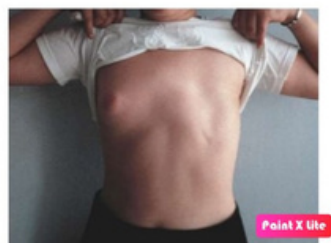
ATHELIA OR AMASTIA

- The absence of nipple and/or glandular breast tissue is a rare occurrence. Ectodermal defects may cause bilateral absence of breasts in males and females and is related to the failure of development of the ectodermal layer and its appendages.

BILATERAL AMASTIA



UNILATERAL AMASTIA



- Bilateral amastia may be an isolated occurrence or be associated with other anomalies of the palate and upper extremities. Unilateral amastia may be a variant of Poland syndrome and should be treated accordingly.

Treatment

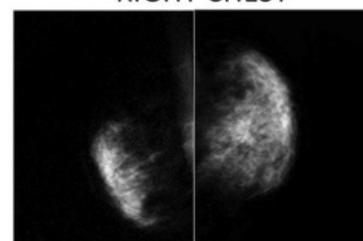
- Treatment should follow the principles of post-oncologic breast reconstruction with special attention paid to the placement of the inframammary fold and nipple. Tissue expansion with autologous and/or prosthetic breast reconstruction techniques is available and should be chosen based on patient and surgeon preference.

- Autologous reconstruction with abdominal, dorsal, or gluteal tissues may be chosen based on body habitus and patient preference. However, in the paediatric population the gluteal tissue transfers may be preferable due to the general availability of soft tissue and the less conspicuous scarring. Abdominal wall weakening and the frequent unavailability of adequate soft tissue make the abdomen a less-appealing donor site in adolescents and young adults as compared with the more mature adults seen with breast cancer.
- Prosthetic reconstruction with tissue expanders and permanent implants follow the same principles as adult reconstruction and can be employed at the surgeon's discretion.

POLAND'S SYNDROME

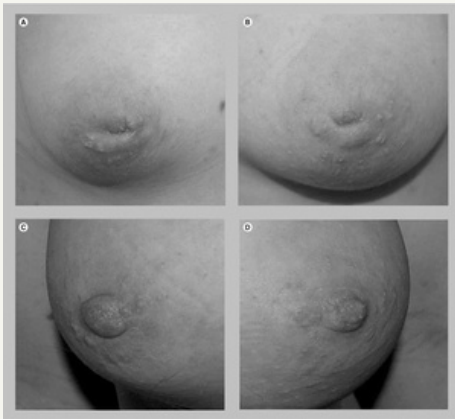
- Poland syndrome is named after Alfred Poland, who described the condition in 1841. It is a combination of chest wall and upper-limb anomalies which can be unilateral or bilateral. It is more frequent in males and on the right side. Most cases are sporadic though there are some reports of genetic transmission.
- The syndrome includes deformation or absence of ribs, partial or total absence of the pectoralis major muscles leading to absence of anterior axillary fold with occasional webbing of axilla. It may be associated with hypoplasia or absence of the breast and areola. The upper limb is often shorter with brachy-syndactyly of the hand. Ipsilateral serratus anterior and the latissimus dorsi muscles may be affected.
- Reconstructive options depend on the presentation and the needs of the patient and various surgical treatment plans are available.

THE MAMMOGRAM SHOWS THE DIFFERENCE BETWEEN THE LEFT CHEST WHERE THE PECTORALIS MUSCLE IS ABSENT AND THE NORMAL RIGHT CHEST



CONGENITAL NIPPLE INVERSION

- Sir Ashley Cooper first described congenital inverted nipples in 1840. It is seen in 2% of the general population with a family history in 50% of patients. The cause for this abnormality is thought to be tethering and shortening of breast ducts and development of fibrous bands behind the nipples during intrauterine life.
- It can cause mechanical problems during breast feeding; however, many can breast feed without any difficulty, probably because of compensatory changes that occur in the breast during pregnancy.



SURGICAL CORRECTION

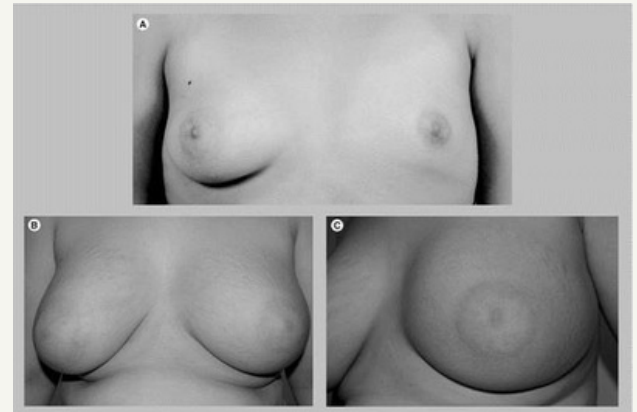
- Most of the procedures involve short circum-areolar incision or an incision at the base of the nipple. The tight bands are stretched, but it is often required to divide the ducts.
- Variety of procedures are described for the surgical correction - tightening of the areolar edge circumferentially and use of adjacent dermal flaps to augment nipple. However, loss of sensation and inability to breast feed are major concerns with surgical procedures.

ASYMMETRY (HYPOPLASIA) OF THE BREAST

- One breast can be hypoplastic. This can occur in isolation or in association with a defect in (one or both) pectoral muscles.
- Some degree of breast asymmetry is common, but it is more pronounced in cases of hypoplasia. This 'true asymmetry' can be treated with various treatment options, including augmentation of the smaller breast with implant or reduction and

mastopexy of the larger breast, or a combination of both these options. Where there is asymmetry in the skin, the use of expanders prior to permanent implant replacement can improve symmetry. To get true symmetry, it may be necessary to operate on both breasts.

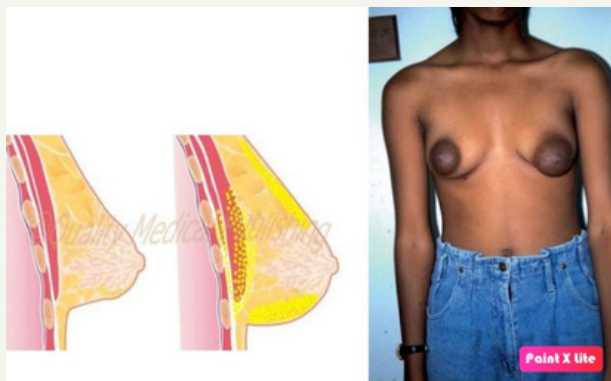- The best age to perform surgery is when the breasts are fully developed - usually approximately at the age of 17 or 18 years. More than one operation may be required. Some hypoplastic breasts can also have a tubular element. Lipofilling (although controversial, its risks and benefits should be discussed with the patients) is useful to provide implant cover and improve contour to obtain a high degree of symmetry.



TUBULAR BREASTS

- Tubular breasts are characterized by normal function/physiology of the breast tissue, but abnormal anatomical shape.
- It can be unilateral or bilateral, and the classical features include some or all of,
 - 1. Lack of breast skin
 - 2. Breast hypoplasia and asymmetry
 - 3. Conical breasts
 - 4. Herniated nipple-areolar complex
 - 5. Large areola and a constricted breast base
- The first correction technique for tubular breasts was described by Rees and Aston in 1976. They suggested widening of the constricted ring at the base of the breast tissue by radial scoring, essentially making cuts at the base of the breast from the centre, similar to the hands of a clock. Several similar techniques to expand the base width have been described, which can include mastopexy and lipofilling.

- The long-term outcome from surgery is not always satisfactory due to loss of sensation, scar issues and asymmetry.



REFERENCES

- 1. Medscape - Congenital Abnormalities of the Breast, Authors: Dhananjay Kulkarni, FRCS, MSc; J. Michael Dixon, FRCS, MD, CME Released: 12/14/2011
- 2. Brown, J, Schwartz, RA. Supernumerary nipples: an overview. *Cutis* 71(5), 344-346 (2003).
- 3. Casey, HD, Chasan, PE, Chick, LR. Familial polythelia without associated anomalies. *Ann. Plast. Surg.* 36(1), 101-104 (1996).
- 4. Ferrara, P, Giorgio, V, Vitelli, O. Polythelia: still a marker of urinary tract anomalies in children? *Scand. J. Urol. Nephrol.* 43(1), 47-50 (2009).
- 5. Latham, K, Fernandez, S, Iteld, L, Panthaki, Z, Armstrong, MB, Thaller, S. Pediatric breast deformity. *J. Craniofac. Surg.* 17(3), 454-467 (2006).
- 6. Lee, HB, Roh, TS, Chung, YK. Correction of inverted nipple using strut reinforcement with deepithelialized triangular flaps. *Plast. Reconstr. Surg.* 102(4), 1253-1258 (1998).
- 7. Trier, WC . Complete breast absence. Case report and review of the literature. *Plast. Reconstr. Surg.* 36(4), 431-439 (1965).
- 8. Dixon, JM, Mansel, RE. ABC of breast diseases. Congenital problems and aberrations of normal breast development and involution. *BMJ* 309 (6957), 797-800 (1994).

- 9. Bartsich, SA, Ofodile, FA. Accessory breast tissue in the axilla: classification and treatment. *Plast. Reconstr. Surg.* 128(1), 35e-36e (2011).
- 10. Down, S, Barr, L, Baildam, AD, Bundred, N. Management of accessory breast tissue in the axilla. *Br. J. Surg.* 90(10), 1213-1214 (2003).
- 11. von Heimburg, D, Exner, K, Krufft, S, Lemperle, G. The tuberous breast deformity: classification and treatment. *Br. J. Plast. Surg.* 49(6), 339-345 (1996).
- 12. Ribeiro, L, Accorsi, A, Buss, A, Pessja, MC. Short scar correction of the tuberous breast. *Clin. Plast. Surg.* 29(3), 423-431, vii (2002).
- 13. Seyfer, AE, Fox, JP, Hamilton, CG. Poland syndrome: evaluation and treatment of the chest wall in 63 patients. *Plast. Reconstr. Surg.* 126(3), 902-911 (2010).
- 14. Darian, VB, Argenta, LC, Pasyk, KA. Familial Poland's syndrome. *Ann. Plast. Surg.* 23(6), 531-537 (1989).

BENIGN BREAST DISEASES

Dr. Sheela V Mane, MD, FICOG, FICMCH

DNB Professor OB-GYN, K C General hospital, Bengaluru, Karnataka.

Dr. Amrita Prabhu, DNB,

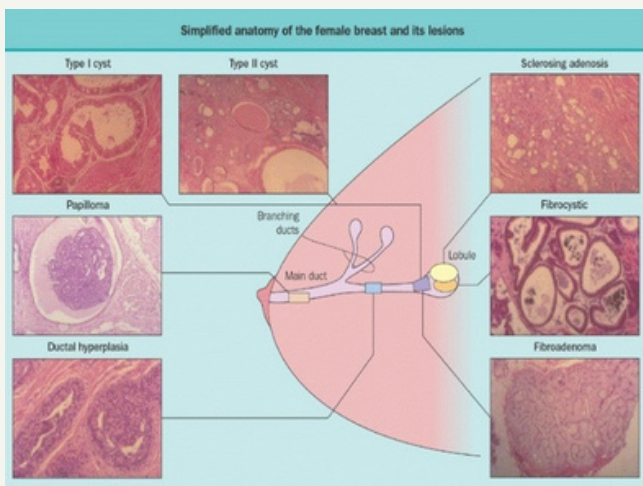
Senior consultant DNB teaching faculty OB-GYN, K C General hospital, Bengaluru

Dr. Tara R, post graduate DNB OB-GYN

K C General hospital, Bengaluru, Karnataka

INTRODUCTION

- Benign breast lesions deserve attention because of their high prevalence, their impact on women's life and due to cancerous potential of some histological types. A firm understanding of benign breast disease is important since sequential steps are necessary to distinguish lesions which impart a high risk of subsequent breast cancer from those which do not.



- **Simplified anatomy of the female breast illustrating the major structural components of the breast, the anatomic location of various lesions, and the histology of those lesions and corresponding sites of origin of potential lesions.**

CLASSIFICATION

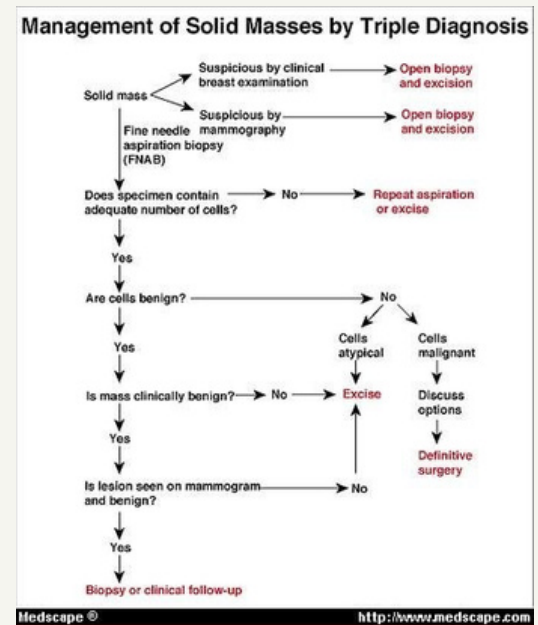
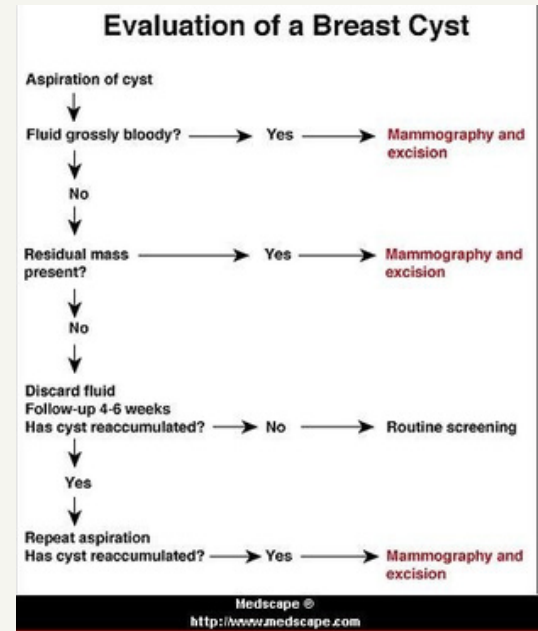
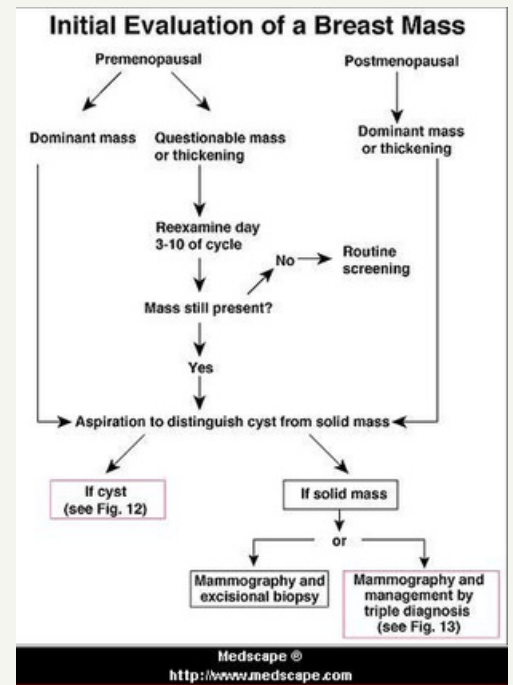
- Currently, two systems are in use to classify benign breast disease : pathologic and clinical.
- **Pathologic classification of benign breast disease** :- Based on findings of biopsy (Pathologic lesions and Relative risk of developing breast cancer)
 - **1. Nonproliferative lesions = No increased risk**
 - Cysts
 - Mild hyperplasia of the usual type
 - Epithelial-related calcifications
 - Fibroadenoma
 - Papillary apocrine change
 - **Proliferative lesions without atypia = 1.5 - 2.0**
 - Sclerosing adenosis
 - Radial and complexing sclerosing lesions
 - Moderate and florid hyperplasia of the usual type
 - Intraductal papillomas
 - **Atypical proliferative lesions = 4.0 - 5.0**
 - Atypical lobular hyperplasia
 - Atypical ductal hyperplasia

CLINICAL CLASSIFICATION OF BENIGN BREAST DISEASE

- Physiologic swelling and tenderness
- Nodularity
- Breast pain
- Palpable lumps
- Nipple discharge
- Breast infections and inflammation

COMMON BENIGN BREAST DISEASES AND THEIR CLINICAL FEATURES

Fibrocystic change	35-55 years of age, rarely seen earlier	Pain/tenderness/nipple discharge/discomfort common in premenstrual phase. Multiple/bilateral breast masses may be present.	Clinical examination-FNA/FNAC/EB.	Reassurance. Self breast examination after menses each month. Vit E(150-600IU/day) or Vit B6(200-800mg/day.)
Mastalgia	Cyclical mastalgia in 3 rd -4 th decade Acyclical mastalgia in 4 th -5 th decade	Breast pain/ache/tenderness Breast engorgement	Clinical breast examination Age appropriate imaging	Reassurance Vitamin supplements Well supporting brassiere. Reduction in fat intake Discontinue hormone therapy Pain score diary.
Fibroadenoma	Most common benign tumour seen between 20-30 years of age usually	Single/multiple masses in the breast usually 2-3cm, but can become larger. Firm smooth, rubbery freely mobile.	Clinical examination Confirm by FNAC/Core needle biopsy	Watch for growth. Excise if more than 3 cm. For multiple fibroadenomas, excision through a single periareolar incision or infra mammary crease.
Phyllodes tumour	Most commonly seen between 3 rd -5 th decade	Isolated masses-sudden increase in size of a pre existing nodule. Can increase upto 50 cm in size. 70%benign 23% malignant 7% borderline.	Mammography Ultrasound FNAC/CNB.	Excision recommended if older age/new mass/size more than 2.5-3cm/suspicious FNAC/CNB/Imaging shows lobulation and intramural cysts.
Nipple discharge	Can present in late teenage - postmenopausal age group	Non neoplastic causes include-galactorrhea/mechanical stimulation/periductal mastitis/subareolar abscess/fibrocystic changes/ mammary duct ectasia Neoplastic causes are-solitary intraductal papilloma/carcinoma/papillomatosis/squamous metaplasia/adenosis. Discharge can be bloody(papilloma/cancer) Milky-increased prolactin/TSH. Bilateral greenish brown discharge-fibrocystic change.	Mammography Ultrasound Fibreoptic ductoscopy	If a mass is present, it should be removed Correct any medical conditions/rule out intake of drugs like OCPS/phenothiazines Chronic unilateral nipple discharge(especially bloody)is an indication for resection of involved ducts.
Breast abscess	Lactational (most common)	Mass in breast of lactating mother associated with redness, pain tenderness and systemic evidence of infection implies a breast abscess. Lactational mastitis-same as above but diffuse breast changes,not localised and no systemic features.	Commonly caused by Staphylococcus aureus	Lactational mastitis-manual pressure, antibiotics, continued breast feeding For an abscess-incision and drainage and discontinue breast feeding
Non lactational breast abscess	Rarely seen	Usually caused by gram positive cocci-Staph aureus most commonly seen. Mixed anaerobes and anaerobic cocci seen.	Ultrasound to detect presence of an inflammatory mass/frank pus/solitary cavity/multiloculated abscess	Aspiration of pus/antibiotic therapy if infection recurs after multiple aspirations, incision and drainage followed by excision of involved lactiferous ducts/ducts at base of nipple may be done during a quiescent period.



CLINICAL GUIDELINES FOR EVALUATION OF NODULES AND DISCHARGE

• Practice Guidelines of the Society of Surgical Oncology [15] recommend the following evaluation:-

- In women less than age 35, all dominant discrete palpable lesions require referral to a surgeon. If vague nodularity, thickening or asymmetrical nodularity is present, the examination is repeated at midcycle after one or two menstrual cycles. If the abnormality resolves, the patient is reassured and if not, referred to a surgeon. Breast imaging may be appropriate.
- In women > age 35 with a dominant mass, a diagnostic mammogram (and frequently a sonogram) (44-47) is obtained and the patient referred to a surgeon. With vague nodularity or thickening, one obtains a mammogram with repeat physical exam at mid-cycle 1 to 2 months later and refers to surgeon if the abnormality persists. Post-menopausal women are referred for surgical consultation after a mammogram.
- Usual practice requires “the triple test” with palpation, mammography (often in conjunction with ultrasonography) and biopsy in women over age 35 with dominant masses. When mammography is negative but a dominant mass is present, biopsy is required to rule out malignancy since lobular carcinoma may not be seen on mammograms.
- For gross cysts (i.e. >4 cm), the guidelines suggest needle aspiration with repeat imaging within six months. If the aspirated fluid does not contain blood, the fluid is discarded without further histologic analysis unless the cyst contains solid components (i.e. complex cyst). If the fluid contains blood or if the cyst is complex, the fluid is sent for cytology and consultation from a surgeon requested.
- For those with a diagnosis of ADH (Atypical Ductal Hyperplasia) on FNA or core biopsy, excisional biopsy is then required since more complete resection often changes the diagnosis to DCIS.

SCREENING AND DIAGNOSTIC BREAST IMAGING

• Self-breast examination

- It should be taught early so that it becomes a normal part of self-care
- Increases breast health awareness
- Promotes early detection of breast cancer (48% of cancers are detected by patients themselves)

DIAGNOSTIC IMAGING

- Asymptomatic (for the breast) women aged 40 years and older should have annual screening mammography preferably using full-field digital mammography and computer-aided detection (CAD). This improves the effectiveness of perception of small nonpalpable malignancies that have the optimum prognosis; for example, more than 90% 10-year disease-free survival when treated.[16]
- Mammograms are reported in a format following the guidelines of Breast Imaging Reporting and Data System (BI-RADS) mandated by the Mammography Quality Standards Act (MQSA) in 1992. The descriptive patterns of mammographic breast density are listed. The mammographic assessment categories are listed below. The radiologist who reads the mammogram should be contacted directly if any part of the report, such as the descriptive patterns, the assessment categories, the mammographic diagnosis, and the specific recommendations, is not clear. A reliable systemic patient tracking and reminder system for mammograms, such as described in the ACOG Clinical Review in November 2002,[17] should be established with written policies clearly documented and rigorously followed.

THE BI-RADS DESCRIPTIVE PATTERNS OF MAMMOGRAPHIC BREAST DENSITY

- The breast is almost entirely fat
- There are scattered fibroglandular densities that could obscure a lesion on mammography
- The breast tissue is heterogeneously dense; this may lower the sensitivity of mammography
- The breast tissue is extremely dense, which lowers the sensitivity of mammography

editors. Diseases of the Breast. Philadelphia: Lippincott Williams and Wilkins; 2000. p. 1-13.

- 4) Going JJ, Anderson TJ, Battersby S, MacIntyre CC. Proliferative and secretory activity in human breast during natural and artificial menstrual cycles. *American Journal of Pathology* 1988;130(1):193-204.
- 5)Love S, Gelman RS, Silen W. Fibrocystic "disease" of the breast—a nondisease? *N Engl J Med* 1982; 307:1010-1014.
- 6) Dupont W, Page D. Risk factors for breast cancer in women with proliferative breast disease. *N Engl J Med* 1985; 312:146-151.
- 7) Dupont W, Parl F, Hartmann W, et al. Breast cancer risk associated with proliferative breast disease and atypical hyperplasia. *Cancer* 1993; 71:1258-1265.
- 8) Zylstra S. Office management of benign breast disease. *Clin Obstet Gynecol* 1999; 42:234-248
- 9)Allen SS, Froberg DG. The effect of decreased caffeine consumption on benign breast disease: a randomized clinical trial. *Surgery* 1987; 101:720-730.
- 10)Ernster VL, Goodson WH 3rd, Hunt TK, Petrakis NL, Sickles EA, Miike R. Vitamin E and benign breast "disease": a double-blind, randomized clinical trial. *Surgery* 1985; 97:490-494.
- 11)Goehring C, Morabia A. Epidemiology of benign breast disease, with special attention to histologic types. *Epidemiologic Reviews* 1997;19(2):310-327.
- 12) Nassar A, Visscher DW, Degnim AC, Frank RD, Vierkant RA, Frost M et al. Complex fibroadenoma and breast cancer risk: a Mayo Clinic Benign Breast Disease Cohort Study. *Breast Cancer Research & Treatment* 2015;153(2):397-405.
- 13) Hartmann LC, Sellers TA, Frost MH, Lingle WL, Degnim AC, Ghosh K et al. Benign breast disease and the risk of breast cancer.[see comment]. *New England Journal of Medicine* 2005;353(3):229-237.
- 14) Kessel B. Premenstrual syndrome. *Advances in diagnosis and treatment. Obstetrics & Gynecology Clinics of North America* 2000;27(3):625-639.
- 15) Goodwin PJ, Neelam M, Boyd NF. Cyclical mastopathy: a critical review of therapy. *British Journal of Surgery* 1988;75(9):837-844.
- 16) Goodwin PJ, Miller A, Del Giudice ME, Ritchie K. Breast health and associated premenstrual symptoms in women with severe cyclic mastopathy. *American Journal of Obstetrics & Gynecology* 1997;176(5):998-1005.
- 17) Ader DN, Shriver CD. Cyclical mastalgia: prevalence and impact in an outpatient breast clinic sample. *Journal of the American College of Surgeons* 1997;185(5):466-470.
- 18) Ader DN, South-Paul J, Adera T, Deuster PA. Cyclical mastalgia: prevalence and associated health and behavioral factors. *Journal of PsychosomaticObstetrics&Gynecology* 001;22(2):71-76.
- 19) Berg JC, Visscher DW, Vierkant RA, Pankratz VS, Maloney SD, Lewis JT et al. Breast cancer risk in women with radial scars in benign breast biopsies. *Breast CancerResearch&Treatment* 2008;108(2):167-174.
- 20) Seltzer MH, Perloff LJ, Kelley RI, Fitts WT, Jr. The significance of age in patients with nipple discharge. *Surgery, Gynecology & Obstetrics* 1970;131(3):519-522.
- 21) Smith GE, Burrows P. Ultrasound diagnosis of fibroadenoma - is biopsy always necessary?[see comment]. *Clinical Radiology* 516;63(5):511-515.
- 22) Apesteguia L, Pina L, Inchusta M, et al. Nonpalpable, well-defined, probably benign breast nodule: management by fine-needle aspiration biopsy and long-interval follow-up mammography. *Eur Radiol* 1997; 7:1235-1239.
- 23) Evron E, Dooley WC, Umbricht CB, et al. Detection of breast cancer cells in ductal lavage fluid by methylation-specific PCR. *Lancet* 2001; 357:1335-1336.
- 24) Kalogeraki A, Panayiotides J, Tamiolakis D, et al. P53 expression in patients with malignant and benign breast diseases. *Anticancer Res* 2000; 20:1801-1806.
- 25) Stark A, Hulka BS, Joens S, et al. Her-2/neu amplification in benign breast disease and the risk of subsequent breast cancer. *J Clin Oncol* 2000; 18:267-274.
- 26) Gilbert F. New screening techniques for breast cancer (MRI). *Dis Markers* 1999; 15:115-116

ABNORMAL NIPPLE DISCHARGE



Dr. Neeta .A. Keshwani, MBBS, DGO.,

Consultant Ob Gyn Keshwani Hospital
Yavatmal, Maharashtra

Dr. Sneha. S. Bhuyar, MD (BJMC Pune), FICMCH, FICOG

Chairperson Breast Committee FOGSI 2019- 2021
Consultant Ob Gyn Dr. Bhuya Hospital, Yavatmal, Maharashtra



- Breast disorders are one of the most common gynaecological problems and nipple discharge is an important presenting symptom. As many as 80% women will experience at least one episode of nipple discharge during their reproductive years.[1] Nipple discharge maybe physiological, pathological, unilateral or bilateral. A careful assessment is required in all cases as the causes for nipple discharge range from benign lactation to underlying malignancy. [2]

- Milk (maybe white, grey, brown) - Lactation (Overall Most common cause), Post lactation period, nipple stimulation, early pregnancy.
- Hypothyroidism, Pituitary adenoma, Antipsychotic medication side effect, etc.

CAUSES OF NIPPLE DISCHARGE

- **Are classified as [3]**
- A. Discharge from a single duct
- B. Discharge from more than one duct
- Blood stained - Intraductal papilloma (Most common cause),
- Intraductal carcinoma, duct ectasia • Serous (any color) - Fibrocystic disease, Duct ectasia, Carcinoma

DISCHARGES FROM MORE THAN ONE DUCT

- Blood stained - Carcinoma, Ectasia (Most common cause), Fibrocystic disease
- Black or green - Duct ectasia (Highly specific)
- Purulent - Infection - Retroareolar abscess, Tuberculosis
- Serous - Fibrocystic disease, Duct ectasia, Carcinoma

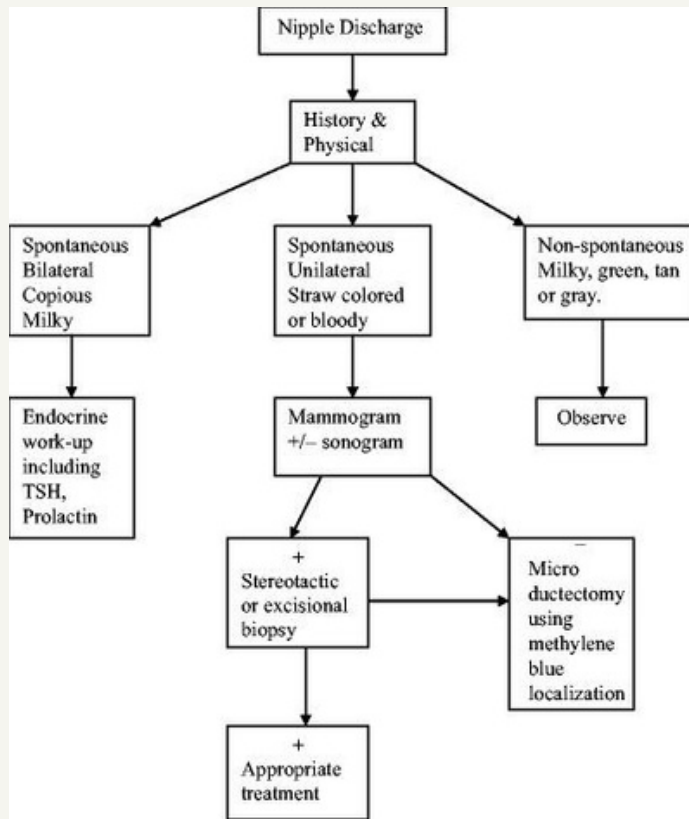
DISCHARGE FROM THE SURFACE

- Paget's disease
- Eczema, Psoriasis
- Chancre
- Risk of malignancy is higher if discharge is from a single duct and even higher if the discharge is bloody. Therefore, the first step in management of a case with any nipple discharge is to exclude malignancy.

CLINICAL APPROACH TO A CASE OF NIPPLE DISCHARGE

- First step is always a detailed history and physical examination. Points during examination include -
- **Pregnancy status** - If pregnant and discharge is bilateral then it is most likely galactorrhea with a benign outcome
- Unilateral / Bilateral
- Color of discharge
- Number of ducts involved
- Presence or absence of lump

• **Fig. 1 Algorithm for management of nipple discharge**



RED FLAGS IN A CASE OF NIPPLE DISCHARGE

• **Which warrant radiological investigation**

- Unilateral discharge
- Bloody/ Serous discharge
- Skin/ Nipple changes
- Lump

NO RED FLAGS

- If discharge is bilateral, milky/ non-bloody, without any red flags then perform
- Pregnancy test
- Guaiac test to rule out blood in discharge
- Sr TSH, Prolactin
- If none of these investigations yield a diagnosis, then perform a Pituitary MRI to look for an adenoma.
- Treatment is cause specific

RED FLAGS PRESENT

- If a lump is evident then proceed with Triple Assessment Algorithm
- Clinical assessment
- Radiology (USG, mammography)
- Histology (FNAC, core needle biopsy)[4]
- A negative cytology report doesn't rule out malignancy. In-situ disease will also not show up on cytology. If lump is not clinically evident, it should be still ruled out.
- MRI for evaluation of nipple discharge is controversial (94.7% sensitive & 78.9% specific in diagnosing malignancy)[5]
- **Next step depends upon number of ducts involved -**
- Ductography is performed in cases of nipple discharge especially if it is bloody
- Cannulating the duct is technically challenging.
- Radiopaque contrast is injected into one or more ducts and mammography is performed.
- It has a sensitivity of 76% for detecting malignancy, specificity of 11%.[6]
- Intraductal papilloma seen as small filling defects surrounded by contrast media. Cancers are visualized as irregular masses or as multiple intraluminal filling defects.
- Duct ectasia shows a dilated cystic structure.
- In single duct discharge, microductectomy is performed and biopsied. It serves diagnostic and therapeutic purpose. If dysplasia/malignancy is found on biopsy, further management needs to be planned.

MICRODUCTECTOMY

- Do not express discharge before performing the procedure. It makes it difficult to identify the affected duct. A lacrimal probe or a stiff nylon suture is inserted into the duct from which the discharge is emerging.

- A tennis racquet incision is made to encompass the entire duct or a peri-areolar incision used and the nipple flap dissected to reach the duct. The duct is then excised.
- In multiple duct discharge - If patient is in symptomatic distress then Radical duct excision with biopsy is done.

HADFIELD'S CONE EXCISION[3]

- The entire major duct system is removed without sacrifice of the breast form. A peri-areolar incision is made and a cone of tissue is removed with its apex just deep to the surface of the nipple and its base on the pectoral fascia. The resulting defect may be obliterated by a series of purse-string sutures although a temporary suction drain will reduce the chance of long-term deformity. Patient must be warned pre-operatively that she won't be able to breast feed after the procedure and may experience altered nipple sensation. It is currently a less preferred procedure.
- If patient not in distress, then a Cytology with ductoscopy or ductal lavage is performed and patient is observed with regular follow ups if no malignancy found.
- Ductoscopy using micro endoscopes is feasible but is generally not revealing.

MAMMARY DUCT ECTASIA

- It is the dilatation of breast ducts with periductal inflammation. Patient generally presents with -
- Nipple discharge of any color (serous discharge is most common, cheesy/green/black is most specific), frequently bilateral
- Subareolar mass
- Abscess
- Mammary duct fistula
- Nipple retraction
- Duct ectasia is diagnosed with the help of USG or ductography.

- If mass / nipple retraction present a carcinoma must be excluded with mammography and negative cytology. In case of persisting suspicion mass should be excised.
- Duct ectasia can be treated conservatively when asymptomatic. [2] Otherwise, Hadfield's operation is done. Care must be taken to shave the back of the nipple to ensure all terminal ducts have been removed otherwise the condition will recur.

INTRADUCTAL PAPILLOMA

- They are true polyps of epithelium lined breast ducts. They are benign lesions with no increased risk of malignancy. Mostly solitary within 4-5 cm of the nipple orifice. Generally <1cm but can grow up to 4-5cm. Common among women aged 30-50 yrs. [2]

CLINICAL FEATURES

- Bloody nipple discharge
- Diagnosis by ductography

TREATMENT

- Microdochectomy - Complete excision of the duct with the tumor.

TAKE HOME MESSAGE

- Nipple discharge is common during a woman's reproductive years even in non-pregnant or non-lactating women. It is usually not serious but it may be the first symptom of an underlying malignancy. Therefore, it does warrant a thorough medical check up.

REFERENCES

1. Hughes LE, Mansel RE, Webster DJ, et al. Benign disorders & diseases of the breast. WB Saunders, London; 2000
2. Kuerer HM. Keurer's breast surgical oncology. New York; Mc Graw Hill; 2010

- 3. Sainsbury R. The Breast. In Bailey & Love's Short Practice of Surgery 26th ed. Williams NS, Bulstrode CJK, O'Connell ER, eds 2013 CRC press, USA Pp 798-819.
- 4. Hussain AN, Policarpio C, Vincent MT. Evaluating Nipple Discharge. Obstet Gynecol. Surv, 2006;61:278-83
- 5. Lorenzon M, Zuiani C, Linda A, et al. Magnetic resonance Imaging in patients with nipple discharge: should we recommend it? Eur Radiol2011;21:899-907
- 6. Morrogh M, Park A, Elkin EB, et al. Lessons learnt from 416 cases of nipple discharge from the breast. Am J Surg 2010;200: 73-80

SCREENING FOR BREAST CANCER



Dr. Mrinalini Mani

HOD, OBG Dept
Guru Gobind Singh Govt. Hospital, New Delhi

Dr. Shashilata Kabra Maheshwari

Senior Specialist, OBG
Deen Dayal Upadhyaya Hospital, New Delhi



- Globally and in India breast cancer is the commonest cancer in women. As per WHO Globacon 2018 reports, nearly 24.2% of all cancers were breast cancers in females, and accounted for 11.6% in both sexes and contributed 6.6% to overall cancer mortality globally. India, United States and China account for almost one third of global breast cancer burden. In India incidence of breast cancer has increased to 11.54% and mortality 13.82%. Rates as high as 25.8 per 100,000 women and mortality of 12.7 per 100,000 have been reported. The main reasons for mortality being lack of awareness, inadequate screening, late diagnosis and unavailability of appropriate treatment. Indian women have two peaks of cancers- a decade earlier than in the West in thirties and forties, which is more aggressive and second peak in postmenopausal 60 years and above.

- Limited resource settings -prioritize **early diagnosis** programmes based on awareness of early signs and symptoms and prompt referral for diagnosis & treatment.
- **Screening** consists of testing asymptomatic women.

WHO POSITION PAPER ON BREAST CANCER SCREENING IN WOMEN- CONCLUSIONS

BREAST CANCER CONTROL (BCC)- WHO RECOMMENDATIONS 2020

- **WHO** promotes BCC within context of comprehensive National Cancer Control Programmes.
- Many low resource countries facing a double burden of breast & cervical cancer need to implement combined strategies addressing both.
- **Primary Prevention** - Control of specific modifiable risk factors: promotes healthy diet, physical activity, control of alcohol intake, overweight & obesity.
- **Secondary Prevention**- For improving outcomes & survival, early detection is critical through early diagnosis and screening.

- Mammography method of choice as insufficient data to support CBE
- Optimal age: 50-69 years Frequency: every 2 years
- **Well-resourced settings**
 - **For 50-69 years**- mammography screening if pre-specified conditions on programme implementation are met.
 - **For women 40-49 or 70-75 years** - can be considered (conditional recommendation)
- **Limited resource settings** - mammography not cost-effective, early detection should focus on reducing stage at diagnosis through improved awareness.
 - With strong health systems, screening at ages 50-69 years is a conditional recommendation
 - In weak health systems, screening is not recommended

COMPONENTS OF BREAST SCREENING EVALUATION

- Breast awareness (patient familiarity with her breasts)
- Physical examination- CBE
- Risk assessment
- Screening mammography
- Screening breast magnetic resonance imaging (MRI).

SCREENING TOOLS

• Mammography

- Only screening method proven to be effective for average risk women.
- Population-based screening reduces breast cancer mortality by ~ 20% across all age groups, in general there appears a narrow balance of benefits compared with harms, particularly in younger and older women.
- Uncertainty about the magnitude of the harms - over diagnosis & over treatment.
- It is resource intensive and there is no research of its effectiveness in low resource settings.

• Self-breast examination

- Women must be educated that BSE should be done both standing with arms at side with hands on hips & arms raised above the head and also while lying down.
- It is important to emphasize that there is often asymmetry of breasts.
- There are three patterns for BSE - the circular, up and down and the wedge pattern. Women can choose any method she is comfortable with. She should use the same method every month.

• Clinical Breast Examination (CBE)

- Research underway to evaluate CBE as a low-cost approach to screening for low resource countries.

- Promising preliminary results show age-standardized incidence rate for advanced-stage breast cancer is lower in screened group compared to unscreened group (Sankaranarayanan, 2011). Sensitivity was around 53%.

• Others

- **Tomosynthesis (3D mammography)** - where BC risk is increased. Limitations- decreased sensitivity for detection of micro calcifications. Currently approved as an adjunct to standard mammography, and does not replace it
- **MRI** - lack of evidence in average-risk; excessive false-positives, high cost.
- **Ultrasonography**- no evidence it improves results over mammography screening for average-risk.

BREAST CANCER SCREENING: CURRENT EVIDENCE

• Whom to screen

- Age-based protocols to determine whom to screen. Strong connection between age and breast cancer risk. Many women developing breast cancer may not fall into a clear high-risk group
- Protocols may be modified for high-risk
- No low-risk groups (except young age) identified in which screening can clearly be omitted

• High risk factors

- History of chest radiation (RR 26.0)
- History of breast cancer (RR varies)
- Extremely dense breasts vs fatty breasts (RR 4.5)
- Biopsy with atypical hyperplasia (RR 3.7)
- Two 1st degree relatives with breast cancer vs none (RR 3.5)
- One 1st degree relative with breast cancer vs none (RR 2.5)
- Menopause >55 yr compared with <45 y (RR 2.0)
- Nulliparity or 1st full-term pregnancy ≥ 30 y (RR 2.0)

- History of benign breast biopsy vs no breast biopsy (RR 1.7)
- Menarche before 12 years vs > 14 years (RR 1.5)
- Postmenopausal obesity vs normal weight (RR 1.5)
- Heterogeneously dense or extremely dense breasts vs fatty or fibro glandular breasts (RR 1.3)
- Current use of combination menopausal hormone therapy vs never users (RR 1.2)
- Moderate alcohol use vs abstention (RR 1.1)

• **Tools for judging the high risk**

- Various tools available to assess risk- NCI Breast Cancer Risk Assessment tool, Breast Cancer Surveillance Consortium, Ontario Family History Assessment tool, Manchester Scoring System, Referral Screening Tool, Pedigree Assessment Tool, Family History Screen 7
- Useful for women with family history of breast cancer
- Help clinicians and patients to understand risk estimates >20% lifetime risk-high risk.

• **Effectiveness of screening in reducing mortality**

- Screening reduces BC mortality in women by 15% - 20% |40-59 years- reduction smaller magnitude and less statistically significant |60-69 years- reduction highly significant|70-74 years- reduction insignificant
- Screening has not been shown to reduce all-cause mortality.

• **Pitfalls of screening**

- **False positive results** - leading to unnecessary follow-up tests, biopsies, anxiety
- **Over diagnosis** - of cancer that would never have progressed to clinical importance in absence of screening. There is also harm of treatment without any benefit

• **Radiation exposure** - may be a small risk

• **When to stop screening in average -risk women**

- No consensus

- BC risk increases with age, 26% breast cancer deaths attributed to diagnosis at >74 yrs
- Continue biennial screening until the remaining life expectancy is about 10 yrs.

• **Frequency of screening**

- Annual screening recommended for all high- risk women
- Biennial screening maintains about 80% mortality benefits of annual screening.
- Different expert groups have offered their recommendations for breast cancer screening and there is no consensus about when to begin and end screening, how often to screen, and by what technique. It is recommended to have formal risk assessment by age 25 for all women. **Table 1** summarizes some of the recommendations.

TABLE 1- Breast Cancer Screening Guidelines for Women

	U.S. Preventive Services Task Force 2016	American Cancer Society 2015	American College of Obstetricians and Gynecologists 2017	International Agency for Research on Cancer 2015	American College of Radiology 2018	American College of Physicians 2019	American Academy of Family Physicians 2016
Women aged 40 to 49 with average risk	The decision to start screening mammography in women prior to age 50 years should be an individual one. Women who place a higher value on the potential benefit than the potential harms may choose to begin biennial screening between the ages of 40 and 49 years.	Women aged 40 to 44 years should have the choice to start breast cancer screening once a year with mammography if they wish to do so. The risks of screening as well as the potential benefits should be considered. Women aged 45 to 49 years should be screened with mammography annually.	After counseling and if an individual desires screening, mammography may be offered once a year or once every two years and clinical breast exams may be offered once a year. Decisions between screening with mammography once a year or once every two years should be made through shared decision-making after appropriate counseling.	There is limited evidence that screening with mammography reduces breast cancer mortality in women 40-49 years of age.	There is sufficient evidence that screening with mammography reduces breast-cancer mortality to an extent that its benefits substantially outweigh the risk of radiation induced cancer from mammography. There is inadequate evidence that clinical breast examination reduces breast cancer mortality. There is sufficient evidence that clinical breast examination shifts the stage distribution of tumors detected toward a lower stage.	Clinicians should discuss whether to screen for breast cancer with mammography before age 50 years. Discussion should include the potential benefits and harms and a woman's preferences. The potential harms outweigh the benefits in most women aged 40 to 49 years.	The decision to start screening with mammography should be an individual one. Women who place a higher value on the potential benefit than the potential harms may choose to begin screening.
Women aged 50 to 74 with average risk	Screening with mammography once every two years is recommended. The evidence is insufficient to assess the additional benefits and harms of clinical breast examination.	Women aged 50 to 54 years should be screened with mammography annually. For women aged 55 years and older, screening with mammography is recommended once every two years or once a year. Women aged 55 years and older should transition to biennial screening or have the opportunity to continue screening annually. Among average risk women, clinical breast examination to screen for breast cancer is not recommended.	Screening with mammography is recommended once a year or once every two years. Decisions between screening with mammography once a year or once every two years should be made through shared decision-making after appropriate counseling. Clinical breast exams may be offered annually. Clinical breast exams should be offered in the context of a shared, informed decision-making approach that recognizes the uncertainty of additional benefits and harms of clinical breast examination beyond screening mammography.	There is sufficient evidence that screening with mammography reduces breast-cancer mortality to an extent that its benefits substantially outweigh the risk of radiation induced cancer from mammography. There is inadequate evidence that clinical breast examination reduces breast cancer mortality. There is sufficient evidence that clinical breast examination shifts the stage distribution of tumors detected toward a lower stage.	Screening with mammography is recommended once a year.	Clinicians should offer screening with mammography once every two years. In average-risk women of all ages, clinicians should not use clinical breast examination to screen for breast cancer.	Screening with mammography is recommended once every two years. Current evidence is insufficient to assess the benefits and harms of clinical breast exams.
Women aged 75 or older with average risk	Current evidence is insufficient to assess the balance of benefits and harms of screening mammography in women aged 75 years or older.	Women should continue screening with mammography as long as their overall health is good and they have a life expectancy of 10 years or more.	The decision to stop screening should be based on a shared decision-making process. The decision making process should include a discussion of the woman's health status and longevity.	Not addressed.	The age to stop screening with mammography should be based on each woman's health status rather than an age-based determination.	In average-risk women aged 75 years or older or in women with a life expectancy of 10 years or less, clinicians should discontinue screening for breast cancer.	Current evidence is insufficient to assess the balance of benefits and harms of screening with mammography.
Women with dense breasts	Current evidence is insufficient to assess the balance of benefits and harms of adjunctive screening for breast cancer using breast ultrasonography, magnetic resonance imaging (MRI), digital breast tomosynthesis (DBT), or other methods in women identified to have dense breasts on an otherwise negative screening mammogram.	Evidence is insufficient to recommend for or against yearly MRI screening.	Other than screening with mammography, the organization does not recommend routine use of alternative or additional tests. Health care providers should comply with state laws that may require disclosure to women of their breast density as recorded in a mammogram report.	There is inadequate evidence that ultrasonography as an adjunct to mammography reduces breast cancer mortality. There is limited evidence that ultrasonography as an adjunct to mammography increases the breast cancer detection rate. There is sufficient evidence that ultrasonography as an adjunct to mammography increases the proportion of false positive screening outcomes.	In addition to mammography, contrast-enhanced breast MRI is also recommended. After weighing benefits and risks, ultrasound can be considered for those who cannot undergo MRI.	There is insufficient evidence on benefits and harms of screening strategies in women who have dense breasts.	Current evidence is insufficient to assess the balance of benefits and harms of adjunctive screening for breast cancer using breast ultrasonography, MRI, DBT, or other methods.

Women at high risk Some organizations release different breast cancer screening guidelines for women who are considered to be at high risk of developing breast cancer. Different screening guidelines may be suggested for women who have risk factors such as a BRCA1 or BRCA2 mutation, who are an untested family member of someone who has a BRCA1 or BRCA2 mutation, who have a history of mantle or chest radiation which occurred before age 30 years, or who have a lifetime breast cancer risk of 20% or greater based on their family history.

Adapted from NCCN www.nccn.org (Document reviewed September 22, 2020)

AMERICAN COLLEGE OF SURGEONS GUIDELINES FOR MRI SCREENING

- MRI Screening annually for young women at risk
- High-risk, but have less than 20% lifetime risk level- biopsy proven atypias, very dense breast tissue, previous BC history. Screening them with MRI is controversial at present. Handle on a case-by-case basis.

NATIONAL COMPREHENSIVE CANCER NETWORK (NCCN) GUIDELINES 2019

- Risk assessment at age 25 years or at a clinical encounter
- **Asymptomatic average risk**
 - 25-39 years- CBE 1-3 yearly, Breast awareness
 - >40years- Annual CBE and Screening mammography, Breast awareness
 - Upper age limit of screening- not yet established. Consider severe comorbid conditions limiting life expectancy (eg. ?10years)
 - Consider Tomosynthesis
- **Asymptomatic High risk**
 - High risk screening and follow up
 - Symptomatic-treat appropriately
- Full -field mammography appears to benefit young women and women with dense breasts.

GOVERNMENT OF INDIA OPERATIONAL GUIDELINES FOR CANCER SCREENING 2019

- GOI advocates screening in the field by ANMs trained in CBE. Any screen positive lady is evaluated by a surgeon at CHC /DH including by ultrasound scan.
- If there is suspicion of malignancy (lump or nipple discharge), biopsy/cytology is done.
- Confirmed cases are referred to a tertiary centre for definitive treatment.

IMPACT OF COVID ON SCREENING AND CURRENT RECOMMENDATIONS

- The risks simply outweigh the benefits when it comes to breast cancer screenings during this COVID-19 pandemic.
- Should recommend postponing screenings and prepare for the consequences once the pandemic subsides.
- Routine screening can be delayed, as generally recommended biennially, deferring by few months should not be of clinical consequence
- With the suspension of non-essential clinical visits, patient education on the early warning signs of breast cancer is a must
- Importance of Self Breast Awareness to be emphasized. If a lady notice changes to the look or feel of the breast, should contact their health care provider.
- Screening mammograms are deferred but diagnostic mammograms must be undertaken

SUMMARY

- Screening mammography reduces BC mortality
- Harms- false- positives, over diagnosis, radiation
- Biennial screening averts 80% deaths
- Decision about screening- consider woman's values and her persona; level of risk
- Annual screening and digital tomosynthesis- most appropriate for women with extremely dense breasts, with 1 or 2 first degree family members with BC
- Reverse MRI for women with very high risk
- For our country- Increase awareness through BSE and involvement of peripheral worker's (ASHA, ANM) for CBE.

BREAST CANCER AND ITS MANAGEMENT



Dr. Charulata Bapaye, MD (Ob Gy),
National Coordinator, FOGSI Breast Committee
Director - GEMS Hospital & Endoscopy Centre, Pune

Dr. Kawita Bapat, MS, FICOG,
VP Elect, FOGSI
Director - One Centre for Gynecological Excellence,
Bapat Hospital, Indore



- The Breast has always been a symbol of Womanhood & ultimate Fertility. As a result, both disease and surgery evoke fear of mutilation & loss of femininity. Cancer of the Breast is one such disease which each and every woman fears for the above reasons along with the dread of cancer.
- ICMR states that Breast Cancer has overtaken Cervical Cancer to become the most common cancer among urban as well as rural women in India.
- Majority of breast lumps are benign, but every breast lump should be regarded as malignant unless proved otherwise.
- The diagnosis and management of breast cancer are undergoing a paradigm shift from a one-size-fits-all approach to an era of personalized medicine. Sophisticated diagnostics, including molecular imaging and genomic expression profiles, enable improved tumor characterization. These diagnostics, combined with newer surgical techniques and radiation therapies, result in a collaborative multidisciplinary approach to minimizing recurrence and reducing treatment-associated morbidity.

RISK FACTORS FOR BREAST CANCER

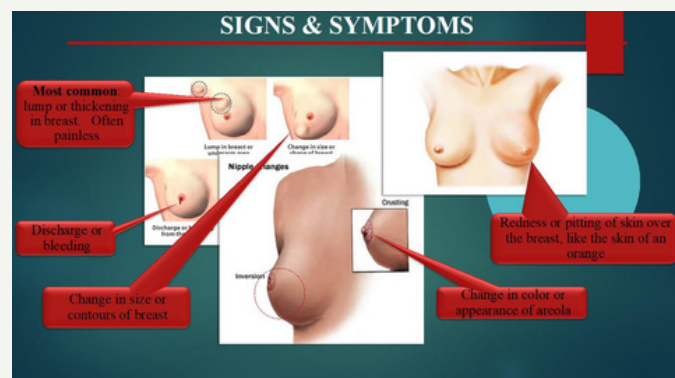
Non Modifiable	Modifiable
Age	Obesity
Gender	Alcohol
F/H of Breast/ Ovarian Cancer	Hormone Replacement Therapy
Early Menarche	Age at first child
Late Menopause	Breast Feeding Practices
Increased Breast Density	
Chest Irradiation	
BRCA1 & BRCA2 Mutation	

SYMPTOMS AND SIGNS OF BREAST CANCER

- The initial symptom is usually an area of thickened tissue in the breast or armpit, usually painless.
- **The other symptoms include**
 - a) Lump in the breast
 - b) Pain in the breast or armpit that does not change with periods
 - c) Pitting/redness of skin of the breast
 - d) Change in size, contours of the breast
 - e) Change in the colour or appearance of the nipple/ areola
 - f) Abnormal nipple discharge or bleeding through the nipple
 - g) Sunken or inverted nipple

QUICK FACTS ABOUT BREAST CANCER IN INDIA [1]

- 1) As many as 17.3 lakh new cases of breast cancer are being diagnosed every year. [2]
- 2) The younger age group patients of Ca breast are fast increasing in our country
- 3) The survival rate post breast cancer treatment is much lesser in India due to delayed diagnosis.



EARLY DIAGNOSIS OF BREAST CANCER

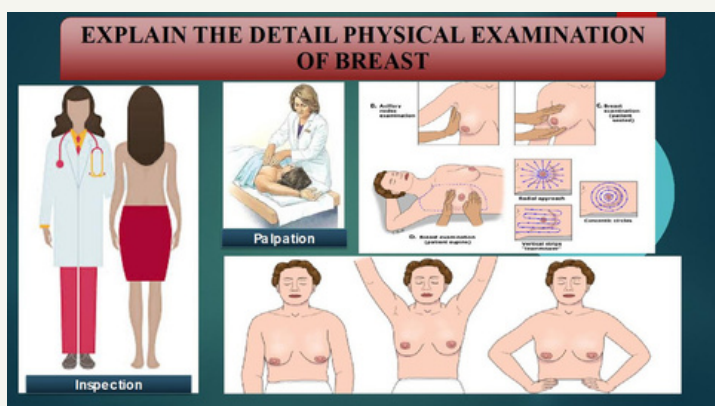
- Although there is no current treatment to prevent breast cancer, early detection of the disease can lead to an excellent outcome.
- It is very important that a woman be aware of the normal appearance and feel of her breasts.
- More than 50% of breast cancers in Australia are diagnosed as a result of investigation of a breast change noted by a woman or her doctor.

SELF BREAST EXAMINATION

- Monthly examination of the breasts in a particular manner post menses (Self Breast Examination) which was taught in the past is now considered obsolete since there is no evidence that BSE reduces mortality from breast cancer.^[2] However, it is of great potential in areas where mammography and regular examinations by physicians is not practicable.

CLINICAL BREAST EXAMINATION

- A clinical Breast examination should be done by a trained health professional. It can be done in the lying down and sitting position with the patient undressed to the waist.



- Inspection & palpation with the flat of the hand either in a radial manner or concentric approach will help to detect a lump or thickening. One cannot forget to palpate the axilla and neck for enlarged lymph nodes. A lump with a hard texture, irregular margins, and puckering of the overlying skin is strongly suggestive of malignancy.

- **A differential diagnosis of** - Fibroadenoma, cysts, chronic abscess (antibioma), and tumours arising from the chest wall & muscles must be kept in mind.

SCREENING MAMMOGRAPHY

- This is the best early detection method for reducing the number of deaths associated with breast cancer. We shall be discussing this modality in the further discussion.

A LUMP IS FELT – HOW DOES ONE PROCEED?

- **The Triple Assessment Algorithm** - Clinical assessment, Radiology & Histology are mandatory in the diagnosis & management of any breast lump.

RADIOLOGICAL INVESTIGATIONS

- Ultrasonography, Mammography & MRI form the basis of the radiological investigations.

ULTRASONOGRAPHY

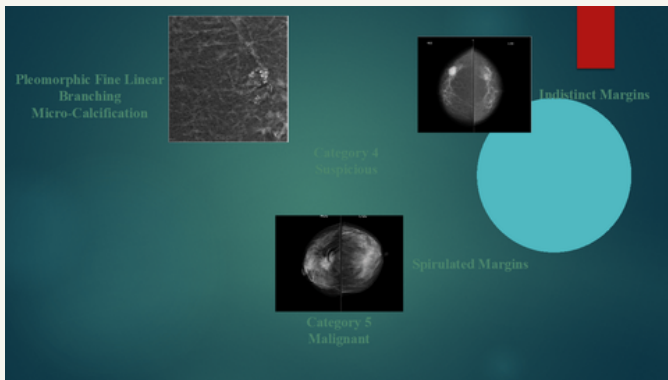
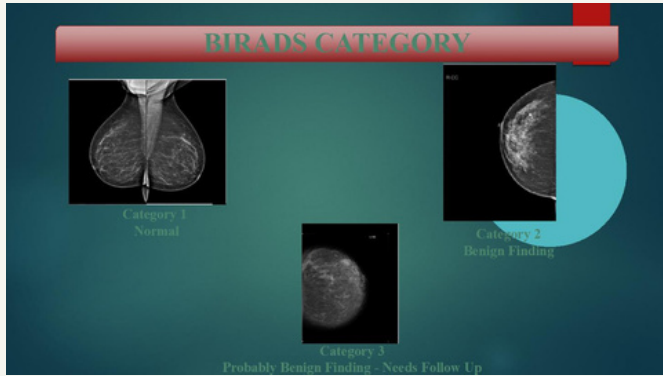
- Ultrasound of the breast was previously used only to differentiate between solid and cystic lesions and for the evaluation of dense breasts. But today, high resolution ultrasound can play a major role in the detection of Ca breast.^[3]
- It can diagnose not only mammographically occult lesions but is also more accurate in identifying lesion characteristics suspicious of malignancy. Its yield is highest among women younger than 50 years of age. It is widely available and cost effective.

MAMMOGRAPHY

- The only screening modality proven to reduce breast cancer-specific mortality is mammography Its ability to diagnose breast cancer may depend on the size of the lump, density of the breast tissue & the skill of the radiologist administering & reading the mammogram.^[4]
- It is less likely to reveal breast tumours in women under 50 yrs of age. The USPSTF (US Preventive Service Task Force) estimates the benefit of mammography in women aged 50 - 70 yrs to be a

30% reduction in the risk of death from Ca Breast and a 17% reduction in risk of death in women aged 40–49 by early detection.

- It is reported in the format of BIRADS Category 1-5. The presence of micro calcifications, mass or architectural distortion may point towards malignancy.



MRI

- MRI is used as a screening test along with mammography in women who have the BRCA mutation or are a very high risk of having Ca Breast. It can also be used to look for the spread of the breast cancer. It has a 95% sensitivity and 26% specificity.[4] Its high cost and limited availability are the major deterrents against its routine use.

BIOPSY

- A breast lump needs to be biopsied for the accurate diagnosis of the lesion. An FNAC, Trucut / Core Needle biopsy, stereotactic/image guided biopsy, Vacuum assisted biopsy or a lumpectomy are the various ways in which tissue can be obtained for histology.
- The Trucut is the preferred type of biopsy and the specimen is subjected to histology & hormone

receptor status (ER, PR, HER2) studies. The diagnosis is usually a Ductal or Lobular carcinoma.

STAGING

- It is staged as follows-

- **Stage 0** - DCIS - Ductal Ca in Situ
- **Stage I** - Lump upto 2cm, not affecting lymph nodes
- **Stage II** - Lump 2-5 cm across & spread to lymph nodes
- **Stage III** - > 5cm lump & spread to lymph nodes
- **Stage IV** - Distant organs like bone, liver, brain, lungs involved

TREATMENT PLAN

- 1) Surgery - Radical/ Conservative
 - 2) Radiation
 - 3) Chemotherapy
 - 4) Hormone Blocking Therapy
 - 5) Biological Treatment (Targetted drug) Treatment
- [5]

- The treatment depends upon
 - a) Type of Cancer
 - b) Stage of Cancer
 - c) Sensitivity to hormones
 - d) Overall health & preference of the patient

SURGERY

- **a) Conservative breast surgery** - This is the primary alternative considered nowadays for the treatment of early cancers. It involves a cosmetic outcome along with good oncological control. A lumpectomy involves removal of the lump along with 1 cm margin of healthy tissue. A quadrantectomy involves removal of a sector of the breast - the lump with a margin of 2 cm of healthy tissue.
- **b) Mastectomy** - Simple mastectomy involves removal of breast lobules, ducts, fatty tissue, nipple, areola and skin.
- **c) Radical Mastectomy** - Involves removal of all of the above and also the pectoralis major muscle and axillary lymph nodes.
- **d) Modified Radical Mastectomy** - This is the most widely practiced surgery for Breast Cancer. It

involves a Mastectomy and axillary lymph node en bloc removal.

RECONSTRUCTION

- Following breast removal, reconstructive surgery (Oncoplasty) can recreate the breast so that there is no disfigurement. It can be done at the same time as the mastectomy or at a later date using a breast implant or tissue from another part of the patient's body.

RADIATION THERAPY

- It is a treatment with high energy rays that destroy the malignant cells. Its main indications are-
 - 1) After breast conservative surgery
 - 2) After a mastectomy if the margins are not cancer free or if the lump was > 5 cm.
 - 3) Stage 4 Ca Breast.

CHEMOTHERAPY

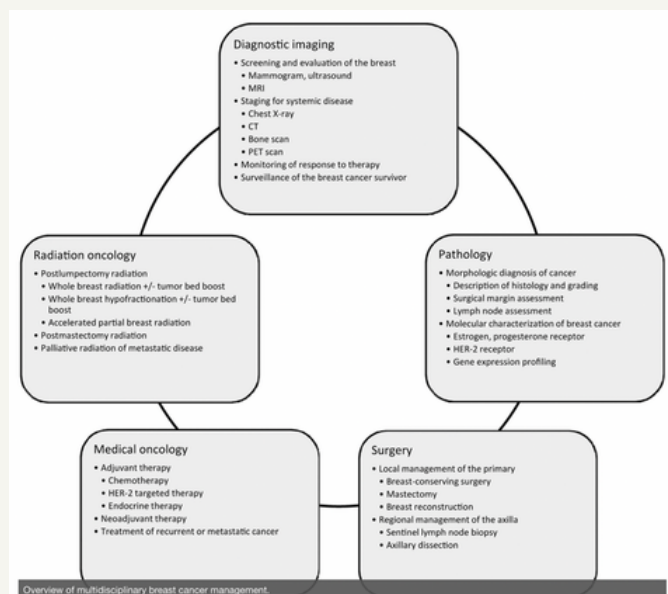
- Cytotoxic drugs may be used as adjuvants if there is a high risk of recurrence or spread.
- Neo adjuvant chemotherapy - If the tumour is large chemotherapy may be administered before surgery to shrink the tumour. Surgery can be performed after the same.
- Chemotherapy can also be used in later stages of Ca Breast to alleviate symptoms.

HORMONE BLOCKING THERAPY

- It is used to prevent recurrence in hormone sensitive breast cancers. (ER, PR +ve cancers).
- **These drugs include -**
 - Tamoxifen
 - Aromatase Inhibitors
 - Ovarian Ablation/Suppression
 - LHRH Agonists (Goserelin)

BIOLOGICAL TREATMENT

- Newer drugs today can alter the behaviour of breast cancer cells. These are referred to as biological targeted therapy. These drugs are Herceptin (Trastuzumab) & Pertuzumab. They are effective in HER2 positive Ca Breast patients.



INFLAMMATORY BREAST CANCERS

- This is a rare, rapidly growing cancer that makes the breast red, swollen & tender. It can easily be mistaken for a breast mastitis or abscess and the diagnosis can be missed.
- It starts as Stage III since it involves the skin. It is an aggressive cancer with poor 5 years survival rates.

SURVIVAL STATISTICS

- A treated woman with Stage 0 or Stage 1 Ca Breast has an almost 100% chance of surviving for at least 5 years.
- If the diagnosis is made at Stage 4 the chance of survival for another 5 yrs is 22%.
- Thus **early diagnosis** is the key to an increased survival rate.
- The Indian Scenario is riddled with gross ignorance regarding Breast care, social & religious taboos and no official Screening programs. We as Gynecologists should make it a point to spend that extra minute with each patient to guide her regarding Prevention & Early diagnosis of Breast Cancer.


REFERENCES

- 1) Breast Cancer – An Overview of published Indian data. Bharath Rangarajan, Tanuja Shet South Asian J Cancer 2016 Jul-Sept; 5(3): 86-92
- 2) Breast Self Examination for the early detection of breast cancer : a USSR/WHO controlled trial in Leningrad V F Semiglazov, Bulletin WHO1987; 65(3);391-396
- 3) The role of ultrasound in the diagnosis of breast cancer Seminars in ultrasound CT and MRI – H M Zonderland, Sept 2000, 21(4):317-24
- 4) Early diagnosis of Breast Cancer – Lulu Wang Sensors(Basel)2017Jul;17(7):1572
- 5) Clinical Diagnosis and Management of Breast Cancer Elizabeth S. McDonald, Amy S. Clark, Julia Tchou, Paul Zhang and Gary M. Freedman Journal of Nuclear Medicine February 2016, 57 (Suppleent 1) 9S-6S;DOI:<https://doi.org/10.2967/jnumed.115.157834>

LEGAL ISSUES IN BREAST DISEASES

Dr. M.C. Patel

Con. Gynecologist and Medicolegal counsellor
Vice President FOGSI 2018



- Due to our social structure a woman prefers to go to the Gynecologist for the suspected lump or any other abnormality related to breast. It is difficult to resist for Gynecologist to treat and many a times delay in diagnosis and treatment may invite poor out come with poor prognosis for the patient and poor legal prognosis for Gynecologist. It must also be remembered that the treatment of the breast diseases involve cosmetic part also.
- In our day to day practice patient may present with one or more of following signs and symptoms related to breast diseases.
 - Lump in breast or thickening that feels different from the surrounding tissue
 - Change in the size, shape or appearance of a breast
 - Skin over the breast changes i.e dimpling, redness or pitting of the skin over breast appearing like the skin of an orange
 - Peeling, scaling, crusting or flaking of the areola or breast skin
 - A newly inverted nipple
- It could be carcinoma also in few of the cases. It is expected from any clinician to diagnose the disease with all necessary investigations and manage accordingly. If the diagnosis is not made in time or the case is not managed properly, it can lead to patient morbidity and mortality,. This can invite litigation in many cases.
- Because of increased awareness, number of consultations for breast complaints are increasing and so the expectations for favourable outcome, on part of patients and their relatives.
- As far as legal part is concerned, there are two types of law,
 - **1) Statutory laws** : Which are enacted and passed in parliaments and after signature of Hon. President of India, published in Government gazette and becomes applicable law.
 - **2) Case laws**: At the time of deciding some cases when no existing law is applicable, honourable courts makes some observation and award judgement as per merits of the case and principle of natural justice which becomes case law and in succession they are taken as precedent during deciding cases and matter in dispute.
- As on today, as such there is no statutory law exactly related to dispute in management of breast diseases. They are decided on merit of the case taking precedent of decided cases.
- Certain observations are taken in to consideration
 - 1. The line of treatment is choice of the doctor provided it is one of the accepted medical practice.
 - 2. When there is more than one school of thoughts about treatment options, treating doctor is at liberty to choose any one or more of them.
 - 3. Unnecessary delay in diagnosis may amount to negligence.
 - 4. Surgery without proper investigations or diagnosis also amounts to negligence.
 - 5. Wrong biopsy report itself is no negligence. It amounts to error of judgement.
 - 6. Before radical surgery it is advisable to obtain written informed consent.
- Let us discuss few of the decided cases

1) S.K.SHARMA V DR.P.B.DESAI.II (2003) CPJ 90 NC

• Facts

- A patient (Gynaecologist) was diagnosed Right sided breast carcinoma
- Chemotherapy started.
- Not examined left breast
- Carcinoma developed in left breast also.
- No investigation including mammography was done for left breast.
- Alleged did not operate and did not follow his views in his published article.
- Pt. died

• Defense on part of doctor was

- Always examined both breasts
- Mammography includes both breasts
- Report was done on 11/4 and consulted on 11/8
- It was advanced stage, Surgery was not possible, so systemic treatment.

• Inference held in court

- Every doctor examines both sides, where paired organs are concerned
- Line of treatment written in his article not followed but circumstances evidences given by way of affidavit becomes final
- Not following his own article does not mean that line adopted (chemotherapy then radiotherapy then surgery)was wrong
- No expert evidence to prove negligence.
- Failed to prove

• Case was dismissed in favor of doctor

2) P.ZAMMEL V DIRECTOR CANCER CENTRE.1995 CTJ 243 KERALA

• Facts

- A case of carcinoma of breast
- Blood sent for CEA on 22/4.
- Report given on 4/7 after death

• Defence

- Kit not available

• Held

- No such clause in receipt and no evidence about non availability
- But as no nexus ,so only Rs. 3000/- awarded

3) S. KISHAN RAO V SUDHA NH 2002 CTJ 58 AP

• Facts

- Operated for big lump in breast
- Biopsy showed cancer
- Recurrence
- Re-operated
- Again recurrence
- Referred to cancer hospital

• Inference Held in court

- Operated without investigations and facility
- Delay in reference

• Judgement

- Case Allowed and awarded Rs.1.5 lakh as compensation

4) M. P. BALAMANI V MED. ADMN. II (2001) CPJ 583 KARNATAKA

• Facts

- Breast lump
- Biopsy suggested adenosis
- Treatment given
- Not improved
- After 45 days slides and block sent to another laboratory for second opinion
- Diagnosed cancer

• Inference Held in court

- Error of judgement
- Even earlier diagnosis would not have made difference

• Judgement

- Held not liable

5)SURANA DIAGNOSIS V SHASHI KAPOOR. IV(2006) CPJ 158 RAJASTHAN

• Facts

- Operated for breast cancer
- Cured after radiotherapy and chemotherapy
- Regular check up every six months
- Patient went for Sonography by her own
- Showed metastasis in liver, lungs and bone

- Surgeon after clinical examination sent for retesting at another place
- Normal report
- Patient stick to her report
- Referred to Tata cancer hospital
- Again normal report

• Defence on part of doctor

- Report shows only possibility of metastasis
- Reports are meant for assisting the treating doctor in reaching a diagnosis looking to the other clinical symptoms and signs and other factors
- To be further confirmed by biopsy

• Held by court

- Mistaken diagnosis is not necessarily a negligent diagnosis
- Case was dismissed in favour of doctor

• Diagnosis of cancer is not always easy for pathologist in Histopathological examination

6) HINABEN BHAVSAR V M.P.SHAH INSTITUTE.I (2006) CPJ502 GUJARAT

• Facts

- Painless tumor in breast
- Provisional diagnosis of fibroadenoma
- FNAC report was of malignancy
- Breast removed
- Biopsy did not show any evidence of malignancy

• Inference held

- Diagnosis of such test would be 50% to approximately 95%

• Judgement

- Case was dismissed in favour of doctor

7) DR. RAVINDRA P. V LAKSHMI RAJAN .II(2007)CPJ 17 NC

• Facts

- Lump in breast
- Went for removal of lump only
- Removed uterus also while removing breast lump in spite of normal sonography report
- Expert testified that it was unwarranted

• Defence

- Referring doctor requested to combine both as patient was poor
- Consent was also taken for the same

• Held in court

- Expert was diploma in Psychology so not accepted
- Pt was prepared for both operation

• Judgement

- Dismissed in favour of doctor

• Expert comment

- Even though this case was decided in favour of doctor, if there is no immediate danger to life of patient, if uterus is not removed and all the reports are normal, merely on ground that referring doctor requested and patient was poor should not be ground for removal of uterus. It should be indicated and valid consent should be taken

8) SMT. D. H. KUMARI V DIRECTOR NIMS.IV(2003) CPJ 441 AP

• Facts

- Pain and swelling in right breast
- FNAC showed cancer
- Advised mammography and removal of breast
- Patient did not go for mammography
- Operated
- Histopathological examination show abscess only
- FNAC slides sent for review in another laboratory did not show cancer

• Defence

- Difficult to diagnose subareolar tumour (literature in support)

• Inference held in court

- Did not follow instruction to go for mammography
- Failed to prove negligent report

• Judgement

- Dismissed in favour of doctor

- **Expert comment**

- If, patient does not follow your instruction and something goes wrong, it becomes contributory negligence on part of patient. It is good defence in favour of doctor. But burden of proof is on shoulder of doctor to prove. So please document it very clearly. please mention everything in case paper.

CARRY HOMES.....

- Proper counseling and valid consent
- Explain possibility of chemo/radiotherapy with/without surgery with outcome and future prognosis
- Proper pre-operative investigations
- Prompt diagnosis with necessary investigations
- Due care during treatment/surgery
- Proper documentation
- Expert opinion whenever needed
- Explain risk involved in surgery/ management
- Surgery must not be performed with out proper facilities
- Arrangement of blood/ blood products
- Qualified Anaesthesiologist
- Confirmed diagnosis of cancer is not possible with out biopsy in many cases.
- It is an accepted medical practice to go for biopsy to confirm diagnosis.
- Diagnosis of cancer is not always easy for pathologist in Histopathological examination also
- Enjoy litigation free practice

Chairperson's Message



Wish you all a very Happy New Year
Hope all of you are in good health

At the outset, I would like to thank our parent organization FOGSI, for giving me this opportunity to serve as Breast Committee Chairperson. We are aiming at breastfeeding promotion, tackling benign breast diseases and breast cancer. We are working with a 3 Tier system- sensitizing our own colleagues by CMEs & Newsletters, training the paramedics and creating awareness among public by organizing various public forums and mass screening programs.

My message to FOGSIans as Breast committee Chairperson is that we are privileged as most of the women come to us for their problems and we should utilize the window of opportunity to do breast examination, so that we can diagnose breast cancer at the earliest. As you all know, it's not the disease per se but its delayed diagnosis and associated complications leading to death and we don't want our women to die of this preventable cause.

I thank FOGSI President respected Dr. Alpesh Gandhi, VP Dr. Ragini Agrawal, Incharge Breast Committee, Secretary General Dr. Jaydeep Tank, all respected advisors, executive members, coordinators and members of Breast Committee for believing in me , guiding me and supporting me in all my endeavours.

Special Thanks to the Editors Dr. Suchitra N Pandit and Dr. Parag Biniwale and all the authors of this e-Newsletter

Thank you all once again

Dr. Sneha S Bhuyar

Chairperson Breast Committee FOGSI 2019 - 2021



Thank you

Designed by S. Kalpana