

**Dr. Prakash Trivedi**

Director- NILES & Aakar IVF Centre, Mumbai  
 Prof & Head of Department- Rajawadi Hospital, Mumbai  
 Endoscopist, ART & Urogynaec. Consultant at Jaslok & BARC Hospital

**Dr. Maya Prasad**

ICOG Certificate Trainee-NILES &  
 Aakar IVF ICSI Centre, Mumbai

The advances in the techniques of operative endoscopy and technological improvement in instrumentation have made it possible to perform laparoscopically almost all the infertility related procedures, previously requiring laparotomy. This not only reduces cost of the treatment, but also has a faster recovery, reduced morbidity and scars, and effective in reducing peritoneal adhesions, thus specifically benefiting fertility potential.

All Reproductive Specialty Centers today are striving to provide assisted reproduction and reproductive surgery at equally advanced level so that patients can be treated according to their personal need.

### *Diagnosis of Infertility*

#### Laparoscopy :

Marked advances in non-invasive diagnostic imaging has limited direct visualization for accurate diagnosis of pelvic disease. Laparoscopy is still a gold standard in work up of infertility, however, it is no more necessary in every patient.

Diagnostic laparoscopy is indicated in cases of anomalies on HSG. Exclusion of bilateral anatomical tubal pathology by diagnostic laparoscopy could avoid unnecessary IVF treatment, by correction of peritubal adhesions. In tubal ligation reversal, the feasibility of sterilization reversal versus straight away referral for IVF can also be determined. Diagnostic laparoscopy can furnish unsuspected information on asymptomatic endometriosis, occult tuberculosis, and assessing the severity and extent of adhesions.

#### Micro laparoscopy :

Micro laparoscopy offers less invasive, direct visual means for diagnosis in infertility and peritoneal factor like tubal adhesions, and results of chromopertubation.

#### Fertiloscopy :

Fertiloscopy has been developed by A. Watrelot in 1997. It is a new minimally invasive method. Through posterior cul-de-sac, a hydroperitoneum is created by inserting a Veress needle, telescope is introduced and inspection of the pelvic organs is carried out. A dye test is performed to test the patency of the tubes. A salpingoscopy is performed by introducing the scope in to the tubal ostia and explore the tubal mucosa. Microsalpingoscopy is performed to examine the tubal cell nuclei which provides an effective means of assessing the functional capacity of the fallopian tubes, the more coloured are the nuclei, the less functioning is the mucosa. A detailed hysteroscopy is the last part of the procedure.

It has limited use since it is a diagnostic procedure and operative laparoscopy cannot be carried out.

#### Role of laparoscopy in infertility surgeries

The various infertility surgeries which can be performed endoscopically include ovarian cystectomy, excision of Endometrioma, Myomectomy, Adhesiolysis, Laparoscopic tubal recanalisation, Neosalpingostomy

### Hydrosalpinx:

A meta-analysis of fifteen retrospective studies comprising of 5592 patients by E Camus, showed negative consequences on pregnancy rate, implantation rates and live birth rates in women with tubal infertility with hydrosalpinx undergoing IVF than women with tubal infertility without hydrosalpinx. It has been suggested that adrenergic denervation and subsequent ovum myosalpingeal transport might explain the poor pregnancy rate in cases with hydrosalpinx.

Hydrosalpinx (Fig. 1) with a diameter of more than 3 cms prior to controlled ovarian hyperstimulation has a high chance of enlargement during the stimulation along with reflux of fluid into the uterine cavity. Instead of Salpingectomy (Fig.2), sonographic aspiration of hydrosalpinx just before ovarian stimulation, while few recommend proximal tubal interruption. Indiscriminate salpingectomy in women with hydrosalpinx is clearly not the consensus.

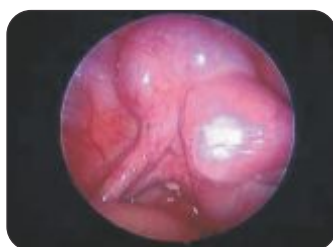

Fig. 1 Left tubal Hydrosalpinx

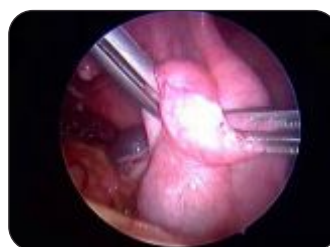

Fig.2 Salpingotomy

Hydrosalpinx, Hematosalpinx or Pyosalpinx would need Salpingectomy in a similar fashion. In Tubo- ovarian abscess, drainage of purulent material and adequate wash with dilute betadine and good antibiotic cover for 48-72 hours does take care.

Our criteria to remove a Hydrosalpinx in an infertile patient are:

- i) Hydrosalpinx more than thumb size or seen easily on transvaginal sonography.
- ii) Pyo or Hematosalpinx.
- iii) Draining in the uterine cavity, especially during the stimulation phase is a definite indication for removal and avoiding embryo toxic effect and we quite often defer embryo transfer, freezing the embryo to transfer after removal of pathology.
- iv) No rugae or mucosal folds on HSG.

Usually Tuberculosis doesn't have classical Hydrosalpinx since the disease is spread via lymphatics and leads to small beaded appearance.

Conservative surgery for hydrosalpinx :

Doubtful role today. A cruciate or a linear incision with a monopolar micro needle with everting sutures of 5 - 0 at four areas from the fimbrial area to a certain distance from there is useful.

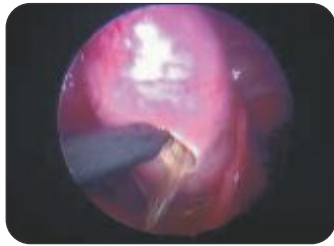

Fig.3 Drainage of the Hydrosalpinx.

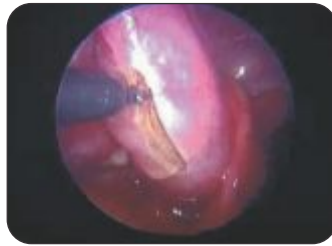

Fig.4 Extension of the incision for salpingotomy.

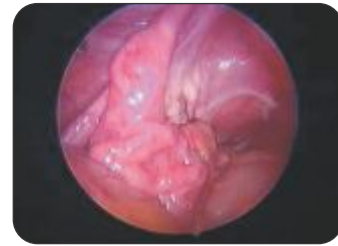

Fig. 5 Appearance at the end of the Procedure.

With natural conception pregnancy rate is never more than 12% since the tubes are diseased and also 8% chances of ectopic pregnancy.

#### Laparoscopic Myomectomy:

Though the cause of formation of fibroids is still not clear, but newer facts do suggests relation between fibroids and infertility.

In infertility myomectomy is indicated if

1. Significantly large fibroid distorting the proximal tuboovarian anatomy.
2. Intracavitary or submucous fibroids causing menstrual disturbances and obliterating the cavity.
3. Large intramural fibroids distorting the endometrial cavity thereby elongating absolute distance of sperm transport.
4. Submucous fibroids causing vascular compromise thereby affecting reproductive nourishment.
5. Submucous fibroid and intramural fibroid with larger cavitory component interfering with proper implantation thereby causing infertility or miscarriage.
6. Cervical fibroids alter the position of cervix and affect fertility.
7. In our research, fibroid tissue produces prolactin and has three times higher level of aromatase leading to localized hyperestrogenemia, which is detrimental to fertility and also increases abortion, hence fibroid of more than 5cms in size, even if intramural with infertility of more than three years or if for IVF or ICSI myomectomy increases conception.

Many gynaecological surgeons viz. Dubuisson, Nezhat, Hasson, Daniell & Gurley have reported moderate to significantly high success of Laparoscopic myomectomy and improved pregnancy rates in patients with associated infertility after laparoscopic removal of fibroids.

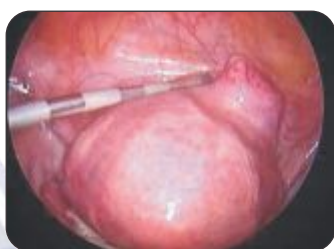

Fig. 6 Subserosal fibroid.

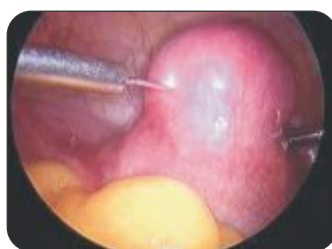

Fig. 7 Vasopressin instillation In to the fibroid.

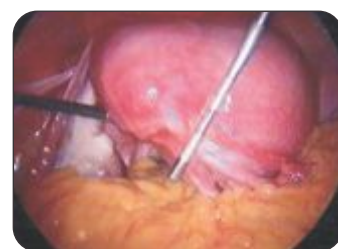

Fig. 8 Palpation of the fibroid With a palpation probe.

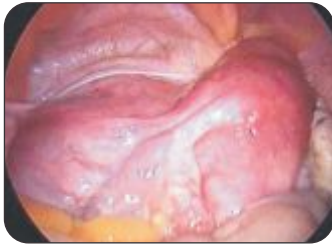

Fig. 9 Broad ligament fibroid.

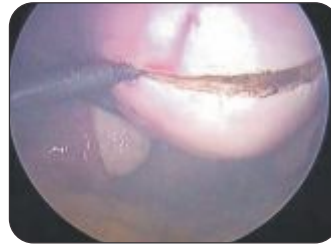


Fig. 10 Incision made with monopolar spatula.

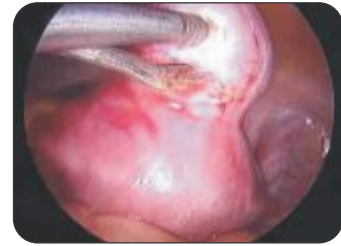

Fig. 11 Fibroid removed with Myoma screw.

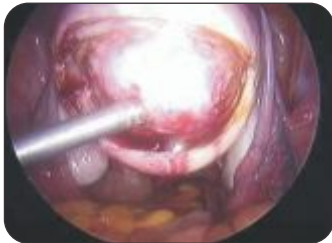

Fig. 12 Fibroid removed with Myoma screw.

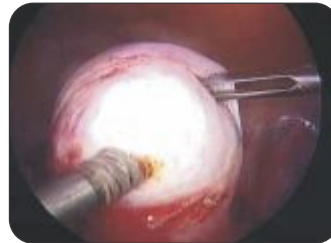

Fig. 13 Traction on the myoma.

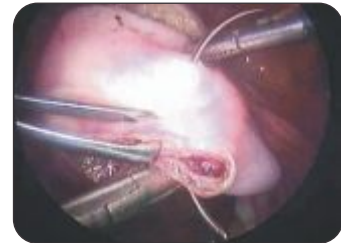

Fig. 14 Intracorporeal Suturing

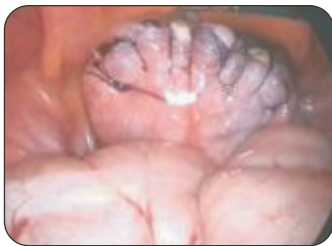

Fig. 15 Final appearance after suturing.

As per author's experiences and many others, removal of fibroid laparoscopically for above mentioned indication has increase pregnancy rate of 40%, which is also true for IVF and ICSI patients. Further this success is improved to 50% if was the fibroid was removed for a donor oocyte program.

### Endometriosis:

Operative laparoscopy and newer drugs like GnRH analogues have brought about a radical change in the treatment of endometriosis with the aim of enhancing fertility.

The goals of conservative procedures are to remove all implants, adhesions, relieve pain, reduce recurrence, reduces post operative adhesion restoring anatomy. In infertile patient, restoration of the normal tuboovarian relationship is essential to enhance fertility.

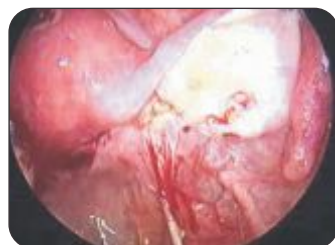

Fig. 16 Right sided chocolate cyst with Posterior adhesions

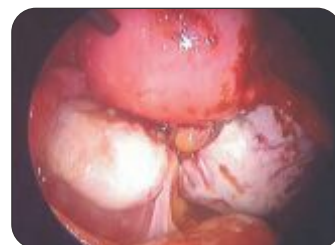

Fig. 17 Bilateral chocolate cyst of ovary.

### Ovarian endometriosis:

Small Endometriomas: It is preferable to under-treat the disease in patients with infertility to avoid excessive destruction of the normal ovarian cortex.

Large endometriomas:

Ovariolysis must precede excision. The drainage of chocolate cyst then peeling of lining of the cyst, coagulated lightly but thoroughly with laser or bipolar forceps, coagulation shrinks and tends to contract and approximate edges of the ovary. Edges are left open to heal.

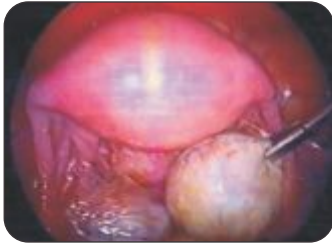

Fig. 18 Intraovarian Endometrioma.

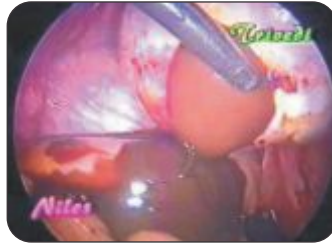

Fig. 19 Drainage of chocolate material.

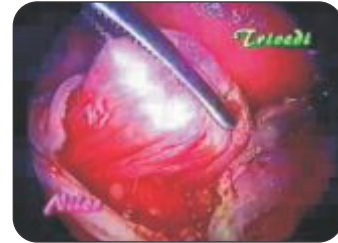

Fig. 20 Peeling of the cyst

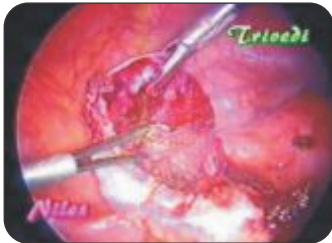

Fig. 21 Fulguration of the base of the Cyst.

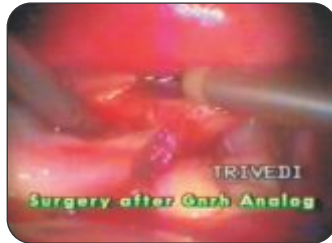

Fig. 22 Surgery after GnRH analogue

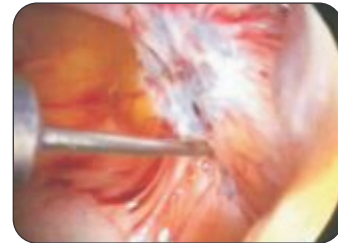


Fig. 23 Peritoneal white fibrotic Lesion

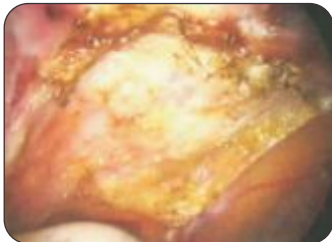


Fig. 24 After Superficial excision and fulguration

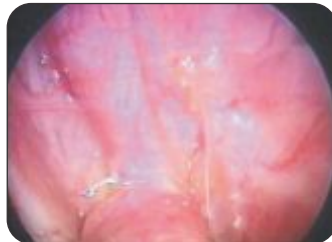


Fig. 25 Jelly like lesions

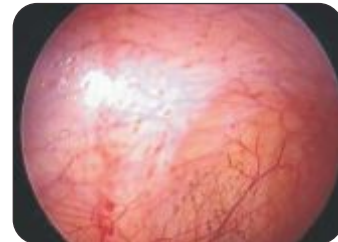
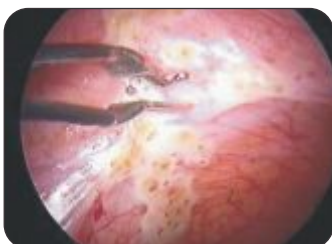
Fig. 26 Scattered lesions.



Laparoscopy vs laparotomy:

Laparotomy has adhesion recurrence rates of 40- 72% and denovo adhesions occurred in over 50% of patients. Faye and Collazo had 58% pregnancy rate after laparoscopy versus 36% after Laparotomy. The use of medical treatments, otherwise successful in alleviating the non reproductive symptoms of endometriosis has failed to demonstrate an improvement in infertility.

Fig. 27 Fulguration of peritoneal lesions.

Donnez in 2912 cases observed that in cases of moderate endometriosis the pregnancy rate was 55% after surgery in the first 10 months while it was 44% in cases of severe endometriosis. The pregnancy rate after repeat surgery was 25%, while the pregnancy rates after the 1st cycle of IVF was 33% and 70% after the 2nd IVF cycle. We came to the conclusion that active fertility management and resorting to ART after surgery has high pregnancy rates.

### Polycystic Ovarian Drilling Or Laparoscopic Ovarian Puncture With Electrocautery

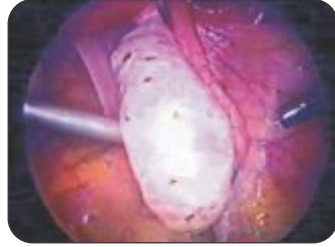

Fig. 28 PCO drilling in process.

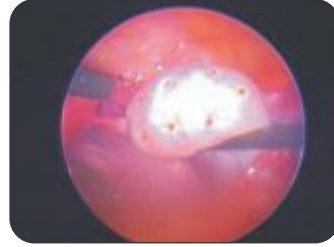


Fig. 29 Completion of the ovarian Puncture.

We do not find any superiority of the contact Lasers in terms of results, hence, we have given up contact Lasers (Fig 30 a,b). Puncturing of the ovaries without electrocautery like a Veress needle can lead to bleeding and some adhesions. The unnecessary scare of adhesions after ovarian puncture with electrocautery is ill founded, since in our experience of more than 1450 cases, no significant adhesions were observed during a caesarean section or a repeat laparoscopy. Adhesions may occur if the wattage kept for Electrocautery or Laser is too high or for longer time.

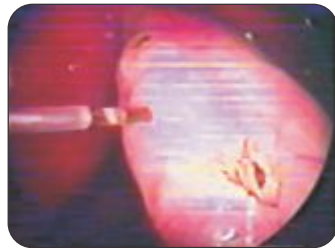


Fig - 30(a)

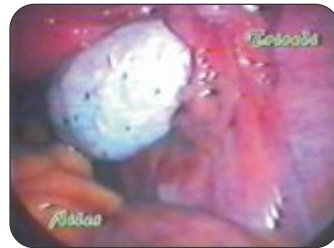

Fig-30(b)

Laser cauterization of the ovarian surface

Similarly the belief that ovarian failure may occur is totally wrong. It has been reported by only one person (Dabirashrafi H 1989) and may be due to improper selection of a case. Hypogonadotrophic PCO patients for e.g. LH levels-3 IU/ml and FSH -1.8 IU/ml need Gonadotrophin stimulation only and no ovarian puncture even if they are sonographically classical polycystic ovaries.

#### Advantage:

There is decreased pregnancy loss and in subsequent ovulation induction ovaries become more responsive and less ovulation induction drugs or Gonadotrophins are needed. Cohort studies report ovulatory rates of 70 - 90 % and pregnancy rates of 40 - 70%. The response is influenced by body weight. Ovulation rate of 96 - 97 % was achieved in slim and moderately obese and 70% in obese patients. Abdel Gadir had an important evaluation of results of Gonadotrophin treatment and ovarian drilling with electrocautery. The pregnancy rates was comparably the same but the abortion rate in Electrocautery ovarian drilled patient was 6-7% as compared to 26 - 28% in the Gonadotrophins only treatment. Miscarriage is due to persistently raised LH levels, which are reduced after ovarian electro cauterization. Also evidence of hyperstimulation is reduced after electrocauterization. Further oocyte quality is better and pregnancy rates are higher, with many surplus oocytes, embryos.

Meta analysis on PCOD drilling reported in 2011 a definite place in treatment of infertile women today though, number of cases are far reduced to barely 15%. Prior to the procedure FSH: LH ratios should be known and if low avoid too many punctures, which can result in ovarian failure. The effect of the procedure lasts for 12 to 18 months.

*Laparoscopy in Infertility*

If pregnancy does not occur after 6 - 12 ovulatory cycles, these patients should be counselled for assisted reproductive techniques. It is wiser to start active fertility treatment after PCO drilling rather than wait and then consider ART.

Laparoscopic Tubal Recanalisation:

Laparoscopic tubal anastomosis is technically demanding and has same results like Open Tubal Microsurgery. This should be considered before jumping to IVF.

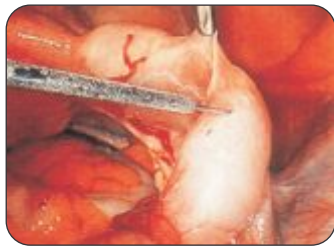


Fig. 31 Vasopressin instillation in the mesosalpinx

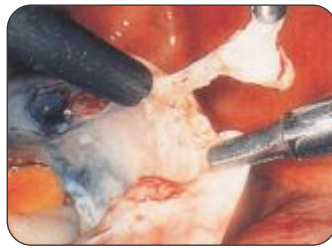

Fig. 32 Transection of the tubal tissue with a microelectrode.

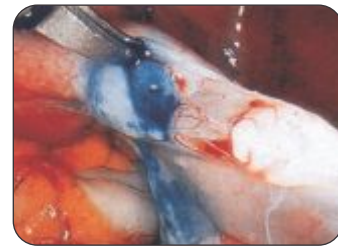


Fig. 33 Patency of the proximal part of the tube

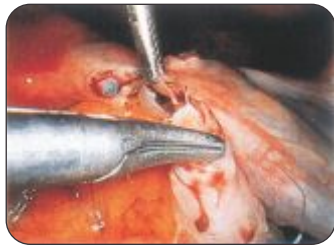


Fig. 34 6 'O' clock suture..

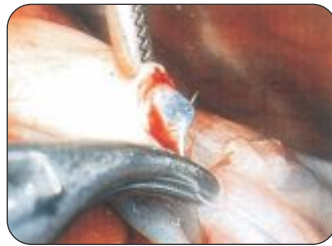

Fig. 35 6 'O' clock suture.

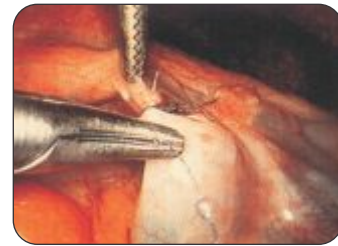

Fig. 36 12 'O' clock suture

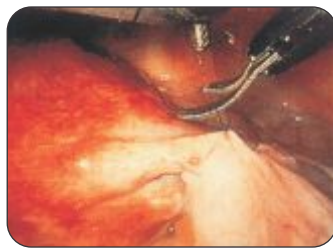

Fig. 37 End of the 12 'O' clock Suture.

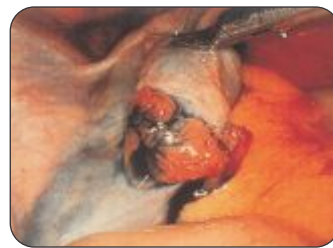

Fig. 38 Tubal patency

Conclusion:

The advent of endoscopic procedures has revolutionized the field of modern gynaecology, especially in infertility. Hysteroscopy has bypassed many conventional surgeries like septal incision, or removal of submucous fibroids or cornual blocks and intra uterine adhesions. Operative laparoscopy for fibroids, endometriosis and many others responsible for infertility has many advantages when the prospect of future fertility is under consideration. The possible damage by bad case selection or poor endoscopic surgeon cannot be overlooked. Operative laparoscopy, if performed by a skilled surgeon, judiciously using the operative modalities best suited for the patient has advantages in maximizing the fertility prospects, in consultation with ART specialist.



**Dr. Nozer Sheriar**  
MD, DNBE, FICOG, FCPS, DGO  
Consultant Obstetrician and Gynecologist  
Breach Candy, Hinduja, Holy Family,  
Masina & Parsee General Hospitals, Mumbai  
Deputy Secretary General - FOGSI  
President - MOGS



**Dr. Nagendra Sardeshpande**  
DNBE, FCPS, DGO  
Consultant Obstetrician & Gynecologist  
Bombay, Brahman Sabha &  
Dhanwantari Hospitals, Mumbai

*'Advance means progress to something better, not progress to something new.'* ~Ogilve

Although the concept of hysteroscopy has existed since since Pantaleoni's procedure in 1869, the technique has become feasible in the last few decades because of rapid advances in optics and instrumentation. Hysteroscopy is now the gold standard for diagnosis and treatment of intrauterine and endocervical pathology such as intrauterine adhesions, submucous myomas and uterine septae.

#### INDICATIONS FOR HYSTEROSCOPY

Hysteroscopy is usually considered in management of infertility following an abnormal HSG, uterine abnormalities detected on ultrasound, following repeated failure of ovulation induction and prior to IVF<sup>1</sup>. It is usually performed along with a concomitant laparoscopy.

##### *Intrauterine Adhesions*

Hysteroscopy is the gold standard for diagnosis and treatment of Asherman's syndrome. Hysteroscopic adhesiolysis results in an 88 - 98% return to normal menstrual cycles<sup>2</sup>. In the absence of other factors related to infertility, 79% of treated patients have normal pregnancies<sup>3</sup>.

##### *Intrauterine Polyps*

Intracavitary lesions such as submucous fibroids and polyps are associated with infertility. Overall, pregnancy rates of 50-78% in infertile women have been reported after hysteroscopic polypectomy<sup>4</sup>.

##### *Submucous Fibroids*

Submucous fibroids causing distortion of the endometrial cavity adversely influence fertility. Hysteroscopic myomectomy has been reported to yield pregnancy rates of 17 – 77 %<sup>5</sup>. For patients with recurrent miscarriage and intracavitary fibroids, surgery increases rates of viable pregnancy outcomes.

##### *Mullerian Anomalies*

Approximately 1 - 2% of all women, 4% of infertile women, and 10 - 15% of patients with recurrent miscarriage have Mullerian anomalies. Uterine septum and the T-shaped uterus have a strong association with subfertility<sup>6</sup>. Hysteroscopy can be used to confirm and treat these conditions.

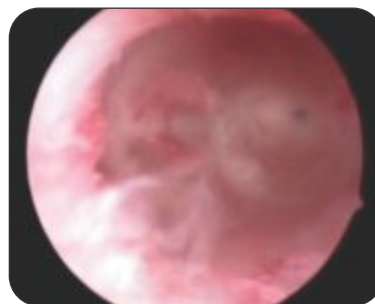


Fig. 1. Unicornuate Uterus



A septum is the most common structural uterine anomaly, accounting for 35% of anomalies and is associated with the highest incidence of reproductive failure. Although a septate uterus may be suspected on HSG or ultrasound, concurrent hysteroscopy and laparoscopy remain the gold standard for diagnosis<sup>7</sup>. Women with a septate uterus and otherwise unexplained infertility may derive modest benefit from metroplasty. In comparison to unexplained infertility and a normal uterine cavity, pregnancy rates have been shown to be significantly higher in women with a septum after removal - 20.4% versus 38.6%<sup>8</sup>.

The Triradiate or T-shaped uterus is associated with the poorest pregnancy outcomes with a term delivery rate of just 21% and spontaneous abortion rates of 47%. Metroplasty for a T shaped uterus has a reported term pregnancy rates of 50 - 88%<sup>9</sup>.

#### *.Proximal Tubal Occlusion*

Caused to infection, intraluminal debris, salpingitis isthmica nodosum, endometriosis or an artifact because of tubal spasm, up to 85% of occlusions can be treated with cannulation, although reocclusion may occur in a third of cases<sup>10</sup>.

#### *Intrauterine Foreign Bodies*

Hysteroscopy can be applied to remove a retained intrauterine device and other foreign bodies (retained products of conception or fetal bones following an incomplete abortion) under direct visualization<sup>11</sup>.

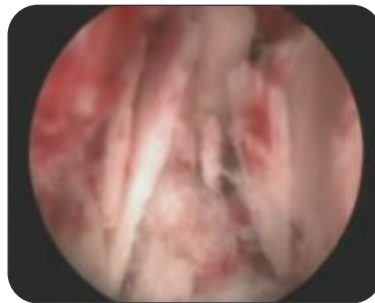


Fig. 2. Retained fetal bones

#### **CONTRAINDICATIONS FOR HYSTEROSCOPY**

The few contraindications of hysteroscopy are cervical or uterine infection, suspected pregnancy or a suspected cervical malignancy. With continuous flow hysteroscopes bleeding is no longer a contraindication in indicated cases.

#### **PREOPERATIVE PREPARATION**

Hysteroscopy must be preceded by accurate history taking, physical examination and an evaluation and mapping of the uterine cavity by pelvic ultrasound and HSG or sonohysterogram.

#### *Antibiotic Prophylaxis*

A diagnostic hysteroscopy does not warrant prophylactic antibiotics except in the presence of valvular heart disease or immunosuppression while a combination of antibiotics such as doxycycline and metronidazole covering aerobes and anaerobes is appropriate during operative hysteroscopic procedures.

#### *Cervical Dilatation*

In patients with expected difficulty preoperative vaginal or oral misoprostol (400 mcg) may assist in cervical

dilation, while a paracervical block with xylocaine 2% may facilitate cervical dilatation and reduce postoperative discomfort.

### *Endometrial Preparation*

While this may decrease blood loss and allow for an easier and more complete resection of submucous myomas in most cases it may be avoided by timing the procedure in the follicular phase or gently clearing the endometrium by MVA. Preparation with a GnRH agonist is mainly indicated for large submucous myomas or following the primary procedure in two stage procedures.

### *DIAGNOSTIC HYSTEROSCOPY*

A 30° 4mm hysteroscope is used with an isotonic solution as a distention medium to visualize the fundus, the lateral walls, cornu, tubal ostia and cervical canal. Almost all intrauterine anomalies are well visualized as distortions and space occupying lesions. The use of an outflow sheath only marginally increases the diameter of the system allowing clearing of blood and debris and better visualization.

The development of smaller instruments and improved flow systems now allow an operative office hysteroscopy to be performed at the same time as initial diagnosis.

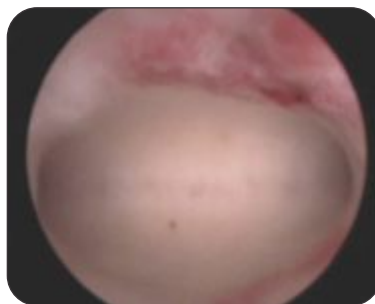


Fig. 3. Hysteroscopy: Normal uterine cavity

Procedures performed in the office setting include targeted endometrial biopsy, adhesiolysis, polypectomy, myomectomy and metroplasty. These procedures can be performed with paracervical block and sedation. The 5 mm Office Continuous Flow Operative Bettocchi hysteroscope includes a 2.9-mm rod lens system, an inflow and outflow sheath and a channel for introducing operating instruments.

### *OPERATIVE HYSTEROSCOPY - TECHNICAL NUANCES*

#### *Hysteroscopic Adhesiolysis*

The standard treatment of intrauterine adhesions is hysteroscopic incision. Fundal adhesions are best divided with a hysteroscopic scissors. The incisions should be divided in small steps without digging into the tissue to avoid perforation. The operative hysteroscope is introduced into the uterine cavity and centrally located synechiae are lysed first. Progression is then made to the margins of the cavity. Thin, filmy adhesions can often be lysed with blunt dissection, but thicker adhesions require transaction or excision. This can be accomplished by incision with a resectoscope or vaporization with bipolar electrocautery. Concurrent use of laparoscopy (direct visualization of the uterus or observing the glow of the hysteroscope at the fundus) or ultrasonography may be useful with extensive adhesive disease to reduce the risk of perforation<sup>12</sup>

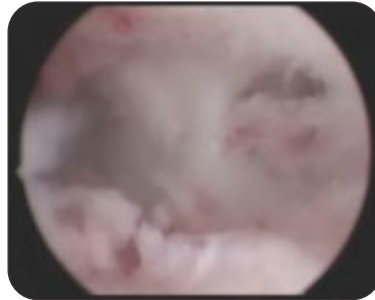


Fig. 4. Intrauterine adhesions before surgery

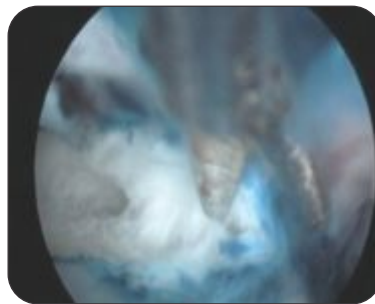


Fig. 5. Hysteroscopic adhesiolysis

### Hysteroscopic Myomectomy

The resection should be limited to the myoma without resecting the adjoining endometrial tissue. After a part of the myoma is removed, the intramural portion of the fibroid inverts into the endometrial cavity. The loop can often be used to separate the fibroid from the pseudocapsule. Using the cutting mode at 80-100 watts provides clean cuts through the myoma. Resection should always start at one side and move horizontally across to the other side.

Whether using monopolar or bipolar current, pressures should stay below 100-120 mm Hg to avoid excessive absorption. The bipolar electrosurgery system (Gynecare Versapoint) offers both a vaporizing electrode and a resecting loop electrode for use with normal saline distention. Vaporizing electrode options include a ball or spring and a twizzle electrode. Obstructed visualization due to floating tissue fragments may necessitate catching the loose tissue with the loop electrode or removing the chips with a sponge holding forceps or an ovum forceps. The Bipolar Chip (E-Vac) System has recently been introduced using a traditional resectoscope with an automatic chip aspirator.

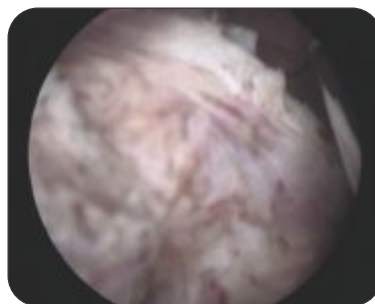


Fig. 6. Hysteroscopic resection of uterine fibroid

Resection of the intramural component of type 2 or 3 myomas is associated with the greatest risk of fluid intravasation, decreasing the chance per procedure of achieving complete resection. After initial excision of the

intracavitary portion of the fibroid, the intramural component will typically expel into the cavity. Repeatedly increasing and reducing the intrauterine pressure often pushes the intramural component into the cavity facilitating excision (hydrostatic massage). In large myomas a two stage procedure may be planned with a GnRH analogue depot administered between stages. This will shrink the myoma and propel the intramural component of the fibroid into the cavity turning it into a type 1 myoma which can be removed at a second stage.

### *Hysteroscopic Septal Incision*

Resection of uterine septum can be performed with scissors or the resectoscope using the bipolar or monopolar Collins knife. When the septum is narrower than 3 cm at the fundus, incising it from distal to cephalic may allow the fibroelastic band to retract reducing bleeding. A broad septum is incised with a lateral, alternating technique of side-to-side resection up to 0.5 cm from the fundus. Then, the remainder is removed from cornua to cornua to avoid damage to this area and to decrease bleeding. It is important to undercut the septum and leave a small shallow convexity at the fundus to avoid perforation.

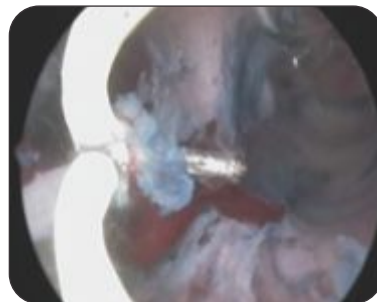


Fig. 7. Resection of uterine septum

### *Hysteroscopic Lateral Metroplasty*

The procedure consists of electrosurgical incision of the lateral walls of the uterine cavity with the help of a resectoscope using a Collins knife. A preoperative HSG or a 3D USG allows the surgeon to have an idea regarding the depth of incision. The incision starts at the upper part of the convergent lateral wall which forms a ridge. The Collins knife is dragged backwards along the lateral wall of the body of the uterus. Care should be taken not to encroach on the lower segment and internal os since incision of this area may cause stenosis or incompetence. The incision is done millimeter by millimeter until the fibrous walls are incised and the underlying pink myometrium is identified. The end point is identification of both cornua satisfactorily on panoramic hysteroscopy.

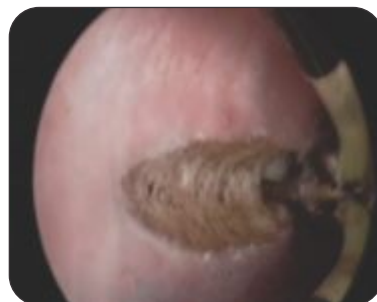

Fig. 8. Hysteroscopic lateral metroplasty for T-shaped Uterus

### *Hysteroscopic Proximal Tubal Cannulation*

A 5 to 7 mm operating sheath is used. The occluded tubal ostia is cannulated with a flexible 5 Fr tubal cannulation catheter, and dilute methylene blue dye is injected through the cannula and observed for spillage through the fimbriated end at laparoscopy. If no patency is documented, the assistant straightens the fallopian tube as the hysteroscopic surgeon slides a hydrophilic guide wire (Terumo) through the initial catheter and into the isthmic area of the fallopian tube. The wire is then withdrawn and patency evaluated.

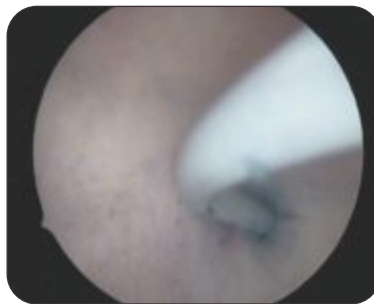

Fig. 9. Hysteroscopic tubal cannulation

### *Postoperative Adhesion Prevention*

Prevention of postoperative adhesion formation begins with minimizing endometrial & myometrial trauma during the initial hysteroscopic procedure. A pediatric Foley's catheter placed into the uterine cavity with the balloon inflated with 3 ml saline provides a simple means to keep the endometrial surfaces apart. Historically, estrogen has been administered following hysteroscopic surgery to encourage endometrial regrowth across the operated surface. Currently the role of estrogen is being questioned.

### *PREVENTION AND MANAGEMENT OF COMPLICATIONS*

Major complications during and following hysteroscopy are extremely rare, the most common complications being bleeding and uterine trauma. The incidence of major and minor complications during operative hysteroscopy is 3.8%<sup>13</sup>.

#### *Mechanical Complications*

Perforation and cervical trauma occur in approximately 0.7-0.8% of cases and commonly occur during cervical dilatation and sometimes during resection of a septum, intrauterine adhesion or a large myoma. Risk factors include cervical stenosis, severe uterine anteversion or retroversion, distortion of the cervical canal due to myomas and adhesions.<sup>14</sup>

Uterine perforations may occur during operative procedures. During septum resection and resection of a fundal or cornual fibroid, care should be taken at the cornua, the thinnest portion of the myometrium. Injuries caused by sharp or electrosurgical instruments may need a diagnostic laparoscopy to identify bleeding or visceral injury. A bleeding rent should be sutured with 1-0 Polyglactin to prevent a potential weakness during future pregnancies. Perforation with an electrosurgical instrument requires immediate exploration with a laparoscope or laparotomy. The risk of peritonitis, sepsis, and death are most often associated with unrecognized and untreated thermal injuries to the viscera, the risk of which must be minimized by safe surgical practices.

#### *Media Related Complications*

The risk of absorption of media is minimal under normal operative conditions. Risk factors for clinically significant intravasation of fluid include prolonged operative procedures, the use of large volumes of low

viscosity media, or the resection of fibroids or myometrial trauma that results in open uterine venous channels, unidentified perforations or extensive hysteroscopic adhesiolysis. Intravasation generally occurs when the intrauterine pressure is greater than the patient's mean arterial pressure.

Fluid overload is rare with electrolyte containing fluids. Nonelectrolyte, hypotonic media, which are nonconductive and are often used for the prolonged, difficult electrosurgical procedures when absorbed in large volumes, may be associated with hyponatremia, hypervolemia, hypotension, pulmonary edema, cerebral edema, and cardiovascular collapse. For every liter of hypotonic media absorbed, the patient's serum sodium decreases by 10 mEq/L. If the patient's sodium level is less than 120 mEq/L, she is at risk for generalized cerebral edema, seizures, and even death. In general, if a fluid deficit is greater than 1500 ml or if the sodium level is less than 125 mEq/L, the procedure should be terminated<sup>15</sup>. Management is by forced diuresis with furosemide (Lasix) 40 mg IV, fluid restriction and administration of 3% sodium chloride with half hourly monitoring of serum sodium levels and osmolality.

#### *Hemorrhage*

Bleeding during or after surgery occurs in 0.25% of cases with myomectomy at the highest risk. GnRH analogues and paracervical injection of vasopressin may reduce the incidence of postoperative bleeding. If bleeding persists after surgery, a 12 Fr. Foley catheter balloon filled with 15-20 mL of fluid may be used as an intrauterine tamponade with uterine artery embolization being a backup.

#### *Infection*

Infection is a rare complication of hysteroscopy. Infection can be suspected on the basis of clinical symptoms (pelvic pain, fever, localized lower abdominal guarding and cervical movement tenderness and investigations (neutrophil leucocytosis, free fluid in POD on ultrasound). Postoperative infections can be treated with a combination of ceftriaxone or cefoperazone, amikacin and metronidazole. Response to therapy can be monitored with evaluation of clinical symptoms<sup>16</sup>.

#### *Conclusion*

Hysteroscopy has revolutionized the management of uterine pathology such as submucous fibroids, uterine septa and Asherman's syndrome not just in terms of their diagnosis but also their management. In a brief span of just two decades hysteroscopy has gone from being a procedure looking for indications to being the gold standard in the management of most intrauterine pathology with the most significant being hysteroscopic fertility enhancing procedure.

#### *References*

1. Balmaceda JP, Ciuffardi I. Hysteroscopy and assisted reproductive technology. *Obstet Gynecol Clin North Am.* 22(3):507, 1995.
2. Friedler S, Margalioth EJ, Kafka I, Yaffe H. Incidence of post-abortion intra-uterine adhesions evaluated by hysteroscopy--a prospective study. *Hum Reprod.* 442, 1993.
3. Schenk LM, Coddington CC 3rd. Laparoscopy and hysteroscopy. *Obstet Gynecol Clin North Am.* 26(1):1, 1999.
4. Stamatellos I, Apostolides A, Stamatopoulos P, Bontis J. Pregnancy rates after hysteroscopic polypectomy depending on the size or number of the polyps. *Arch Gynecol Obstet.* 277(5):395, 2008.
5. Di Spiezo Sardo A, Mazzon I, Bramante S, Bettocchi S, Bifulco G, Guida M. Hysteroscopic myomectomy: a comprehensive review of surgical techniques. *Hum Reprod Update.* 14(2):101, 2008.
6. Homer HA, Li TC, Cooke ID. The septate uterus: a review of management and reproductive outcome. *Fertil Steril.* 73(1):1, 2000.
7. Sheriar NK. Management of congenital uterine abnormalities, In *Pregnancy at Risk – A Practical Approach to High Risk Pregnancy and Delivery*, Krishna UR, Shah DS, Salvi VA, Sheriar NK, Damania KR (Eds), FOGSI, Jaypee, 2010.



### *Hysteroscopy in Infertility*

8. Mollo A, De Franciscis P, Colacurci N, Cobellis L, Perino A, Venezia R. Hysteroscopic resection of the septum improves the pregnancy rate of women with unexplained infertility: a prospective controlled trial. *Fertil Steril*, 91(6):2628, 2009.
9. Barranger E, Gervaise A et al. Reproductive performance after hysteroscopic metroplasty in the hypoplastic uterus: a study of 29 cases. *Br J Obstet Gynecol*, 109(12): 1331, 2002.
10. Kodaman PH, Arici A, Seli E. Evidence-based diagnosis and management of tubal factor infertility. *Curr Opin Obstet Gynecol*, 16(3):221, 2004.
11. American College of Obstetricians and Gynecologists. Hysteroscopy. ACOG Technical Bulletin Number 191-April 1994. *Int J Gynaecol Obstet*. 45(2):175, 1994.
12. Sheriar NK, Sardeshpande N. Hysteroscopic management of intrauterine adhesions. In *Endoscopy in infertility*, Rao K, Chen C (Eds), Jaypee, 2007.
13. Loffer FD. Contraindications and complications of hysteroscopy. *Obstet Gynecol Clin North Am*, 22(3):445, 1995.
14. Jansen FW, Vredevoogd CB, van Ulzen K, Hermans J, Trimboos JB, Trimboos-Kemper TC. Complications of hysteroscopy: a prospective, multicenter study. *Obstet Gynecol*. 96(2):266, 2000.
15. Morrison DM. Management of hysteroscopic surgery complications. *AORN J*, 69(1):194, 1999.  
Cooper JM, Brady RM. Late complications of operative hysteroscopy. *Obstet Gynecol Clin North Am*, 27(2):367, 2000

**Dr. Milind R. Shah**

MD, DGO, DFP  
 2<sup>nd</sup> Vice President Elect of FOGSI (2011)  
 Past Chairman - Rural Obstetrics Committee of FOGSI (2004-08)  
 Past President - Solapur OBGY Society (2001-2002)  
 Executive Committee Member - ISOPARB

The incidence of hormonal disorders in infertility is not very low as it was thought about in past. In fact, due to advances in medical technologies in diagnosis of endocrine malfunction and with better understanding of pathophysiology of these disorders, clinicians are able to treat them aptly with better conception rates.

Endocrine system produces very important hormones that are necessary for normal human reproduction. Abnormal hormonal production can result in infertility. Another important thing one must understand is these hormonal disorders are not only important in the face of infertility but these women are prone to chloasma, breast lumps, uterine fibroids, immune system diseases, osteoporosis, hyperlipidemia and other diseases. In female infertility, FSH, LH, prolactin from pituitary glands, estrogen, progesterone, DHEA from ovaries, insulin from pancreas, thyroid hormones from thyroid gland & GnRH from hypothalamus are important. Let us discuss in short only thyroid disorders, hypoprolactinemia, diabetes mellitus & adrenal dysfunction as other topics like PCOD, luteal phase defect, hypogonadotropic hypogonadism and premature ovarian failure will be covered elsewhere.

Amongst all these polycystic ovarian syndrome (PCOS) is the most common hormonal disorder among women, which affects an estimated 7 percent of women. However, many cases may go undiagnosed, so as many as one in 10 women may be affected.

Thyroid dysfunction:

Thyroid hormones can affect reproductive potential of an individual. Excess or deficiency of this hormone affects male and female reproductive function.<sup>1</sup>

The effect of severe hyperthyroidism on fertility is well documented but the effects of mild and moderate degree of hyperthyroidism is not very clear.<sup>2</sup> In male increased concentration of thyroxine, leads to increased levels of sex hormone binding globulins, which in turn leads to increased level of both estradiol & testosterone since estradiol is less bound to SHBG, the bioavailability of estrogen is higher, resulting in hyperestrogenic state accounting for gynaecomastia, spider angiomas, decreased libido, & impair spermatogenesis.<sup>3</sup>

In female similar cascade occurs leading to elevated levels of estradiol & testosterone. At the same time follicular phase baseline FSH & LH levels are also raised with an attenuated midcycle LH surge. Consequently there are various defects in ovulation with a wide range of menstrual disorders ranging from amenorrhoea to menometrorrhagia.<sup>5</sup>

Diagnosis is on the basis of clinical picture & assessment of thyroid function test. Further testing is done for radioactive iodine uptake, imaging & antithyroid antibodies levels. Treatment is either medical, surgical or by radiotherapy. In infertility cases, antithyroid drugs would be the best option. Fortunately with treatment, hormone levels return to normal & reproductive potential is regained.

Hypothyroidism is by spectrum of thyroid disorders. Severe & moderate degrees of hypothyroidism affect the reproductive systems of both males & females, but mild or subclinical hypothyroidism doesn't have much influence on infertility. In males, it causes decreased libido & testicular disturbances.<sup>4</sup> In females it is basically anovulation but other related manifestations are menstrual irregularities, spontaneous first trimester abortions, stillbirths & premature deliveries.<sup>6</sup> Diagnosis is by very typical clinical manifestations & serological



examinations like sensitive TSH assay. Later antibodies to thyroglobulin & antimicrosomal antibodies are useful predictors for progression risk. Treatment is with supplementation of thyroxine. There is always a question mark of role of thyroid replacement therapy in smaller doses where there is ovulatory dysfunction. Only answer could be long term randomized multicentric control trial which is lacking to date.

#### Hyperprolactinemia:

15% to 25% of irregular ovulation is caused by hyperprolactinemia which interferes with both ovulation and embryo implantation in the uterus. It affects HPO axis but also has effect on ovary itself which is responsible for menstrual irregularities seen in hyperprolactinemia.<sup>7</sup> It also regulates ovarian steroidogenesis by its action on the aromatase enzyme.<sup>8</sup> It also has role in luteal phase defect leading to infertility. Eventually it also causes adenomyosis which affects sperm migration, embryo implantation and subsequent growth.<sup>9</sup>

Serum prolactin is measured in the morning after an overnight fast or before lunch provided there are no midmeal snacks as levels are affected by variety of things like food, diurnal variation etc. Single elevated level need to be confirmed second or third time. Further investigation are radiological examination of sella turcica, sometimes CT or MRI, and also thyroid function tests and baseline FSH/ LH evaluation.

Treatment is medical, surgical or by irradiation. Medical therapy is preferred as now there are many drugs available. It also has significant impact on male reproduction. By acting on hypothalamo-pituitary-gonadal axis. Prolactin affects gonadal function, seminal plasma, accessory reproductive gland function and even sexual behavior. Many a times this part is not taken seriously by clinicians. Hyperprolactinemia affects the pulsatile release of LH by anterior pituitary, which in turn leads to decreased testosterone synthesis. It also inhibits 5 alpha reductase activity which adversely affects spermatogenesis apart from causing structural changes in testes.

#### Adrenal dysfunction:

Adrenalin is a hormone which is released by the adrenal glands during conditions of stress. Although it helps to escape from danger, it also inhibits our ability to utilize progesterone, a very important hormone for fertility. Hypofunction leads to Addison's disease and hypofunctions produces Cushing's syndrome due to deficiency of glucocorticoids, adrenal virilism due to androgen excess and hyperaldosteronism due to increased aldosterone. Many a times presentation of adrenal disorders is in the form of abnormal menstrual pattern, anovulation and infertility.<sup>10</sup> In Cushing syndrome, increased plasma ACTH concentrations stimulate increased adrenocorticoid secretion, thus inhibiting hypothalamic corticotrophin releasing hormone secretion and other factors from the pituitary. This aberration in the cycle as well as changes in the secretory patterns, are thought to influence the mechanisms involved in ovulatory function. It is thought to cause impaired LH response to GnRH.

In adrenal insufficiency there is loss of axillary and pubic hair in women and decreased libido. Women with autoimmune adrenal insufficiency are at increased risk of premature ovarian failure and anovulation.

#### Diabetes Mellitus:

As we know that diabetes affects almost all systems of body, it also hits fertility as well. Basically in males it causes decreased libido, erectile dysfunction. Retrograde ejaculation is also common in diabetic males due to nerve damage. In females, it is insulin resistance which leads to hormonal imbalance, decreased libido and many a time's problems which are due to associated obesity. Formation of ovarian cysts is also very commonly associated finding in diabetic infertile women. Insulin resistance and PCOS is another problem which needs proper correction to achieve pregnancy.

#### References:

### *Hormonal Disorders*

1. Becas GP et al: Thyroid disease & pregnancy, *Med Clin North Am* 75:121,1991
2. Clyde HR et al: Elevated plasma testosterone & gonadotrophin levels in infertile males with hyperthyroidism, *Fertil Steril* 27:662,1976
3. Kidd GS et al: The hypothalamopituitary testicular axis in thyrotoxicosis, *J Clin Endocrinol Metab* 48:798,1979
4. Wortsman J et al: Abnormal testicular function in men with primary hypothyroidism, *Am J Med* 82: 207, 1987
5. Goldsmith RE et al: The menstrual pattern of thyroid disease, *J Clin Endocrinol Metab* 12: 846,1962
6. Davis Le et al: Hypothyroidism complicating pregnancy, *Obstet Gynecol* 72: 108, 1988
7. Murray FT et al: Return of gonadal function in man with prolactin secreting pituitary tumours, *J clinical endocrinol Metab* 59: 79, 1984
8. Martikinen H et al: Prolactin suppression by bromocriptin stimulates aromatization of testosterone to estradiol in women. *Fertil Steril* 1989
9. Mori T et al: Animal model of uterine adenomyosis is prolactin a potent inducer of adenomyosis in mice
10. Sabatine L, androgen excess: [www.emedicine.com/med/topic3489,htm](http://www.emedicine.com/med/topic3489.htm) last updated 2007